



National Comprehensive
Cancer Network®

NCCN Clinical Practice Guidelines in Oncology (NCCN Guidelines®)

Merkel Cell Carcinoma

Version 1.2022 — November 17, 2021

NCCN.org

Continue



National
Comprehensive
Cancer
Network®

NCCN Guidelines Version 1.2022

Merkel Cell Carcinoma

[NCCN Guidelines Index](#)
[Table of Contents](#)
[Discussion](#)

Chrysalyne D. Schmults, MD, MS/Chair ☞ ¶
Dana-Farber/Brigham and Women's
Cancer Center

Rachel Blitzblau, MD, PhD/Vice Chair §
Duke Cancer Institute

Sumaira Z. Aasi, MD ☞
Stanford Cancer Institute

Murad Alam, MD, MBA, MSCI ☞ ¶ §
Robert H. Lurie Comprehensive Cancer
Center of Northwestern University

James S. Andersen, MD ¶ ¶
City of Hope National Medical Center

Brian C. Baumann, MD §
Siteman Cancer Center at Barnes-
Jewish Hospital and Washington
University School of Medicine

Jeremy Bordeaux, MD, MPH ☞
Case Comprehensive Cancer Center/
University Hospitals Seidman Cancer
Center and Cleveland Clinic Taussig
Cancer Institute

Pei-Ling Chen, MD, PhD ≠
Moffitt Cancer Center

Robert Chin, MD, PhD §
UCLA Jonsson Comprehensive Cancer Center

Carlo M. Contreras, MD ¶
The Ohio State University Comprehensive
Cancer Center - James Cancer Hospital
and Solove Research Institute

Dominick DiMaio, MD ≠
Fred & Pamela Buffett Cancer Center

Jessica M. Donigan, MD ☞
Huntsman Cancer Institute
at the University of Utah

Jeffrey M. Farma, MD ¶
Fox Chase Cancer Center

Maxwell A. Fung, MD ☞ ≠
UC Davis Comprehensive Cancer Center

Karthik Ghosh, MD ¶
Mayo Clinic Cancer Center

Roy C. Grekin, MD ☞ ¶
UCSF Helen Diller Family
Comprehensive Cancer Center

Kelly Harms, MD, PhD ☞
University of Michigan Rogel Cancer Center

Alan L. Ho, MD, PhD †
Memorial Sloan Kettering Cancer Center

Ashley Holder, MD ¶
O'Neal Comprehensive Cancer Center at UAB

John Nicholas Lukens, MD §
Abramson Cancer Center at the
University of Pennsylvania

Theresa Medina, MD †
University of Colorado Cancer Center

Kishwer S. Nehal, MD ☞ ¶
Memorial Sloan Kettering Cancer Center

Paul Nghiem, MD, PhD ☞
Fred Hutchinson Cancer Research
Center/Seattle Cancer Care Alliance

Soo Park, MD †
UC San Diego Moores Cancer Center

Tejesh Patel, MD ☞ ≠
St. Jude Children's Research Hospital/
University of Tennessee Health Science
Center

Igor Puzanov, MD, MSCI †
Roswell Park Comprehensive Cancer Center

Jeffrey Scott, MD, MHS ☞
The Sidney Kimmel Comprehensive
Cancer Center at John Hopkins

Aleksandar Sekulic, MD, PhD ☞
Mayo Clinic Cancer Center

Ashok R. Shaha, MD ¶ §
Memorial Sloan Kettering Cancer Center

Divya Srivastava, MD ☞
UT Southwestern Simmons
Comprehensive Cancer Center

William Stebbins, MD ☞ ¶
Vanderbilt-Ingram Cancer Center

Valencia Thomas, MD ☞
The University of Texas
MD Anderson Cancer Center

Yaohui G. Xu, MD, PhD ☞
University of Wisconsin
Carbone Cancer Center

NCCN
Mai Nguyen, PhD
Beth Lynn, RN, BS

☞ Dermatology
¶ Internal medicine
† Medical oncology
§ Otolaryngology
≠ Pathology/Dermatopathology
¶ Reconstructive surgery
§ Radiotherapy/Radiation oncology
¶ Surgery/Surgical oncology
* Discussion Section Writing Committee

Continue

[NCCN Guidelines Panel Disclosures](#)



National
Comprehensive
Cancer
Network®

NCCN Guidelines Version 1.2022

Merkel Cell Carcinoma

[NCCN Guidelines Index](#)
[Table of Contents](#)
[Discussion](#)

[NCCN Merkel Cell Carcinoma Panel Members](#)
[Summary of the Guidelines Updates](#)

[Clinical Presentation, Preliminary Workup, Diagnosis, Additional Workup, and Clinical Findings \(MCC-1\)](#)
[Primary and Adjuvant Treatment of Clinical N0 Disease \(MCC-2\)](#)
[Primary and Adjuvant Treatment of Clinical N+ Disease \(MCC-3\)](#)
[Treatment of Clinical M1 Disease \(MCC-4\)](#)
[Follow-up, Recurrence, and Treatment \(MCC-5\)](#)

[Principles of Pathology \(MCC-A\)](#)
[Principles of Radiation Therapy \(MCC-B\)](#)
[Principles of Excision \(MCC-C\)](#)
[Principles of Systemic Therapy \(MCC-D\)](#)

[Staging \(ST-1\)](#)

Clinical Trials: NCCN believes that the best management for any patient with cancer is in a clinical trial. Participation in clinical trials is especially encouraged.

Find an NCCN Member Institution:
<https://www.nccn.org/home/member-institutions>.

NCCN Categories of Evidence and Consensus: All recommendations are category 2A unless otherwise indicated.

[See NCCN Categories of Evidence and Consensus.](#)

NCCN Categories of Preference: All recommendations are considered appropriate.

[See NCCN Categories of Preference.](#)

The NCCN Guidelines® are a statement of evidence and consensus of the authors regarding their views of currently accepted approaches to treatment. Any clinician seeking to apply or consult the NCCN Guidelines is expected to use independent medical judgment in the context of individual clinical circumstances to determine any patient's care or treatment. The National Comprehensive Cancer Network® (NCCN®) makes no representations or warranties of any kind regarding their content, use or application and disclaims any responsibility for their application or use in any way. The NCCN Guidelines are copyrighted by National Comprehensive Cancer Network®. All rights reserved. The NCCN Guidelines and the illustrations herein may not be reproduced in any form without the express written permission of NCCN. ©2021.



Updates in Version 1.2022 of the NCCN Guidelines for Merkel Cell Carcinoma from Version 1.2021 include:

MCC-1

- Footnote c revised: Imaging is encouraged in most cases of MCC. Imaging is *indicated* whenever metastatic or unresectable disease is suspected based on H&P findings... (Also page MCC-2A, MCC-3, MCC-5)
- Footnote e added: As immunosuppression in MCC is a risk factor for poor outcomes, immunosuppressive treatments should be minimized as clinically feasible in consultation with the relevant managing physician. As immunosuppressed patients are at high risk for recurrence, more frequent follow-up may be indicated. (Also page MCC-4, MCC-5)

MCC-2

- Management of the Primary Tumor:
 - ▶ Following ≥1 baseline risk factor, category revised: ~~Narrow margin~~ *Excision with individualized margins and multimodal therapy determined from multidisciplinary assessment including radiation oncology.*
- Management of the Draining Nodal Basin:
 - ▶ Following SLN negative, second option revised: *May consider RT to the nodal basin in high-risk patients at increased risk for a false-negative SLNB.*

MCC-2A

- Footnotes revised:
 - ▶ Footnote h: Baseline risk factors: larger primary tumor (>2.1 cm); chronic T-cell immunosuppression, HIV, CLL, solid organ transplant; head/neck primary site; lymphovascular invasion present.
 - ▶ Footnote j: ~~In the head and neck region, risk of false-negative SLNBs is higher due to aberrant lymph node drainage and frequent presence of multiple SLN basins. If SLNB is not performed or is unsuccessful, consider irradiating nodal beds for subclinical disease. Consider empiric RT to the nodal basin when: 1) the accuracy of SLNB may have been subject to anatomic compromise (lymphoma involved nodes, or history of remote lymph node excision); 2) when the risk of false-negative SLNB is high due to aberrant lymph node drainage and presence of multiple SLN basins (such as in head & neck or midline trunk MCC); or 3) when identified by lymphoscintigraphy in cases of profound immunosuppression (ie, solid organ transplant recipients). See Principles of Radiation Therapy (MCC-B).~~

MCC-2A (continued)

- ▶ Footnote l: SLNB is typically performed at this time.
- ▶ Footnote n: ~~Mohs micrographic surgery (MMS) or GCPDMA~~ *other forms of peripheral and deep en face margin assessment (PDEMA), using margins similar to WLE [wide-local-excision] wide local excision (WLE), may be appropriate. See NCCN Guidelines for Squamous Cell Skin Cancer - Principles of GCPDMA PDEMA Technique for description of GCPDMA PDEMA.*
- ▶ Footnote s: ~~Neoadjuvant~~ *Adjuvant chemotherapy may be considered in select clinical circumstances; however, available retrospective studies do not suggest survival benefit for neoadjuvant/adjuvant chemotherapy. No data are available to support the adjuvant use of immunotherapy outside of a clinical trial. See Principles of Systemic Therapy (MCC-D). (Also page MCC-3)*
- Footnote removed: Consider RT when there is a potential for anatomic (eg, previous history of surgery including WLE), operator, or histologic failure (eg, failure to perform appropriate immunohistochemistry on SLNs) that may lead to a false-negative SLNB. Consider RT in cases of profound immunosuppression.

MCC-3

- Clinical N+:
 - ▶ Header revised: Clinical N+ (*regional MCC*).
- Management of the Draining Nodal Basin, Positive, following M0:
 - ▶ Third bullet revised: Clinical trial for neoadjuvant or adjuvant therapy preferred if available.
 - ▶ New bullet added: Consider neoadjuvant immunotherapy.
- Footnote t added: See Principles of Systemic Therapy (MCC-D).

[Continued](#)

UPDATES



Updates in Version 1.2022 of the NCCN Guidelines for Merkel Cell Carcinoma from Version 1.2021 include:

MCC-4

- Clinical M1:
 - ▶ Header revised: Clinical M1 (*Disseminated MCC*).
- Footnote v revised: Under highly selective circumstances, in the context of multidisciplinary consultation, resection of ~~oligometastasis~~ *limited metastases* can be considered. (Also page MCC-5)

MCC-5

- Footnote removed: As immunosuppressed patients are at high risk for recurrence, more frequent follow-up may be indicated. Immunosuppressive treatments should be minimized as clinically feasible, in consultation with their managing physician.
- Footnote w added: Patients at high risk of recurrence include those who are immunosuppressed and patients who have positive non-SLN metastases.

MCC-B 1 of 2

- Following Resection of Primary MCC:
 - ▶ Removed: or Consider observation.
- Footnote removed: Consider observation of the primary site in cases where the primary tumor is small (eg, <1 cm) and widely excised with no other adverse risk factors such as LVI or immunosuppression.

MCC-B 2 of 2

- SLNB without LN dissection, SLN negative revised: SLN negative - RT not *routinely* indicated, ~~unless at risk for false-negative SLNB~~.
- Footnotes removed:
 - ▶ Consider RT when there is a potential for anatomic (eg, previous WLE), operator, or histologic failure (eg, failure to perform appropriate immunohistochemistry on SLNs) that may lead to a false-negative SLNB.
 - ▶ In the head and neck region, risk of false-negative SLNB is higher due to aberrant lymphatic drainage and frequent presence of multiple SLN basins. If SLNB is unsuccessful, consider irradiating draining nodal basin for subclinical disease.
 - ▶ Consider RT to draining nodal basin identified by lymphoscintigraphy in cases of profound immunosuppression (ie, solid organ transplant recipients).

MCC-B 2 of 2 (continued)

- Footnote 3 added: Consider empiric RT to the nodal basin when:
 - 1) the accuracy of SLNB may have been subject to anatomic compromise (lymphoma involved nodes, or history of remote lymph node excision); 2) when the risk of false-negative SLNB is high due to aberrant lymph node drainage and presence of multiple SLN basins (such as in head & neck or midline trunk MCC); or 3) when identified by lymphoscintigraphy in cases of profound immunosuppression (ie, solid organ transplant recipients).

MCC-C

- Surgical Approaches:
 - ▶ Second sub-bullet revised: If adjuvant RT may not be indicated (See MCC-2), *perform* wide excision with 1- to 2-cm margins to investing fascia of muscle or pericranium when clinically feasible and consistent with reconstruction and radiation goals listed below.
 - ▶ Third sub-bullet revised: Techniques for more exhaustive histologic margin assessment may be considered (Mohs micrographic-surgery, CCPDMA or other forms of PDEMA), provided they do not interfere with SLNB when indicated.
- Footnote 2 revised: ~~If *When* Mohs micrographic surgery is used, a debulked specimen of the central portion of the tumor should be sent for permanent vertical section microstaging. being performed and the staging information required to properly treat the tumor, submission of the central specimen for vertical paraffin-embedded permanent sections or documentation of staging parameters in Mohs report is recommended.~~
- Footnote removed: CCPDMA = complete circumferential peripheral and deep margin assessment.

[Continued](#)

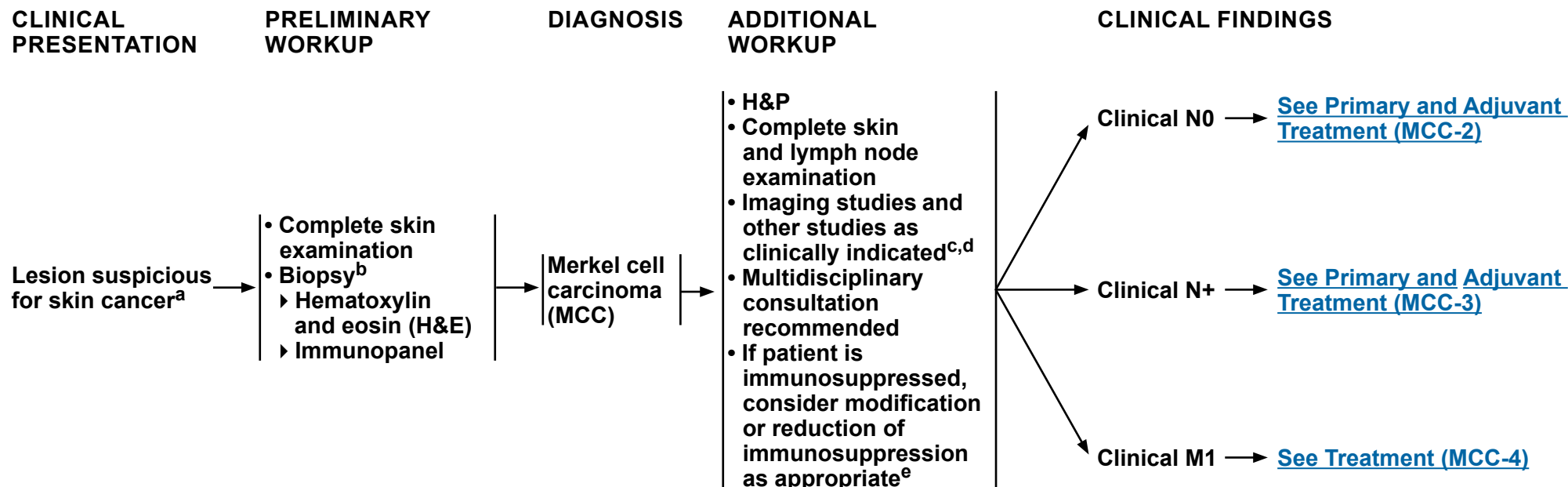
UPDATES



Updates in Version 1.2022 of the NCCN Guidelines for Merkel Cell Carcinoma from Version 1.2021 include:

MCC-D

- Header revised: Local Disease *N0*
 - ▶ First bullet revised: *For primary disease*, adjuvant chemotherapy is not recommended.
- Header revised: Regional Disease *N+*
 - ▶ Bullet removed: For recurrent regional disease, consider pembrolizumab if curative surgery and curative RT are not feasible.
 - ▶ Second bullet revised: *For regional disease*, ~~neoadjuvant/adjuvant~~ chemotherapy is not routinely recommended ~~for regional disease~~ as survival benefit has not been demonstrated in available retrospective studies, but could be used on a case-by-case basis if clinical judgment dictates. No data are available to support the adjuvant use of immunotherapy outside of a clinical trial.
 - ▶ Options useful in certain circumstances:
 - ◊ Option added: Neoadjuvant nivolumab.
 - ▶ Bullet added: For recurrent regional disease, consider pembrolizumab if curative surgery and curative RT are not feasible.
- Header revised: Disseminated Disease *M1*
 - ▶ Preferred interventions, Pembrolizumab: reference 4 added.
- Reference added: Topalian SL, Bhatia S, Amin A, et al. Neoadjuvant nivolumab for patients with resectable Merkel cell carcinoma in the CheckMate 358 Trial. J Clin Oncol 2020;38:2476-2487.



^a For more information, see American Academy of Dermatology Association: <https://www.aad.org/public/diseases/skin-cancer/merkel-cell-carcinoma>.

^b [See Principles of Pathology \(MCC-A\)](#).

^c Imaging is encouraged in most cases of MCC. Imaging is indicated whenever metastatic or unresectable disease is suspected based on H&P findings. Occult metastatic disease that resulted in upstaging has been detected in 12%–20% of patients presenting without suspicious H&P findings (Singh N, et al. J Am Acad Dermatol 2021;84:330-339). Whole-body PET with fused axial imaging (CT or MR) or chest/abdomen/pelvis CT with contrast, with neck CT if primary tumor on head/neck or brain MRI if clinical suspicion, may be useful to identify and quantify regional and distant metastases. Several studies indicate whole-body PET with fused axial imaging is more sensitive for detecting occult metastatic disease at baseline. Imaging may also be useful to evaluate for the possibility of a skin metastasis from a noncutaneous primary neuroendocrine carcinoma (eg, small cell lung cancer), especially in cases where CK20 is negative. The most reliable staging tool to identify subclinical nodal disease is sentinel lymph node biopsy (SLNB) (George A, et al. Nucl Med Commun 2014;35:282-290; Hawryluk EB, et al. J Am Acad Dermatol 2013;68:592-599; Siva S, et al. J Nucl Med 2013;54:1223-1229).

^d Quantitation of serum Merkel cell polyomavirus (MCPyV) oncoprotein antibodies may be considered as part of initial workup; seronegative patients may have a higher risk of recurrence; in seropositive patients, a rising titer may be an early indicator of recurrence; baseline testing should be performed within 3 months of treatment, because titers are expected to decrease significantly after clinically evident disease is eliminated.

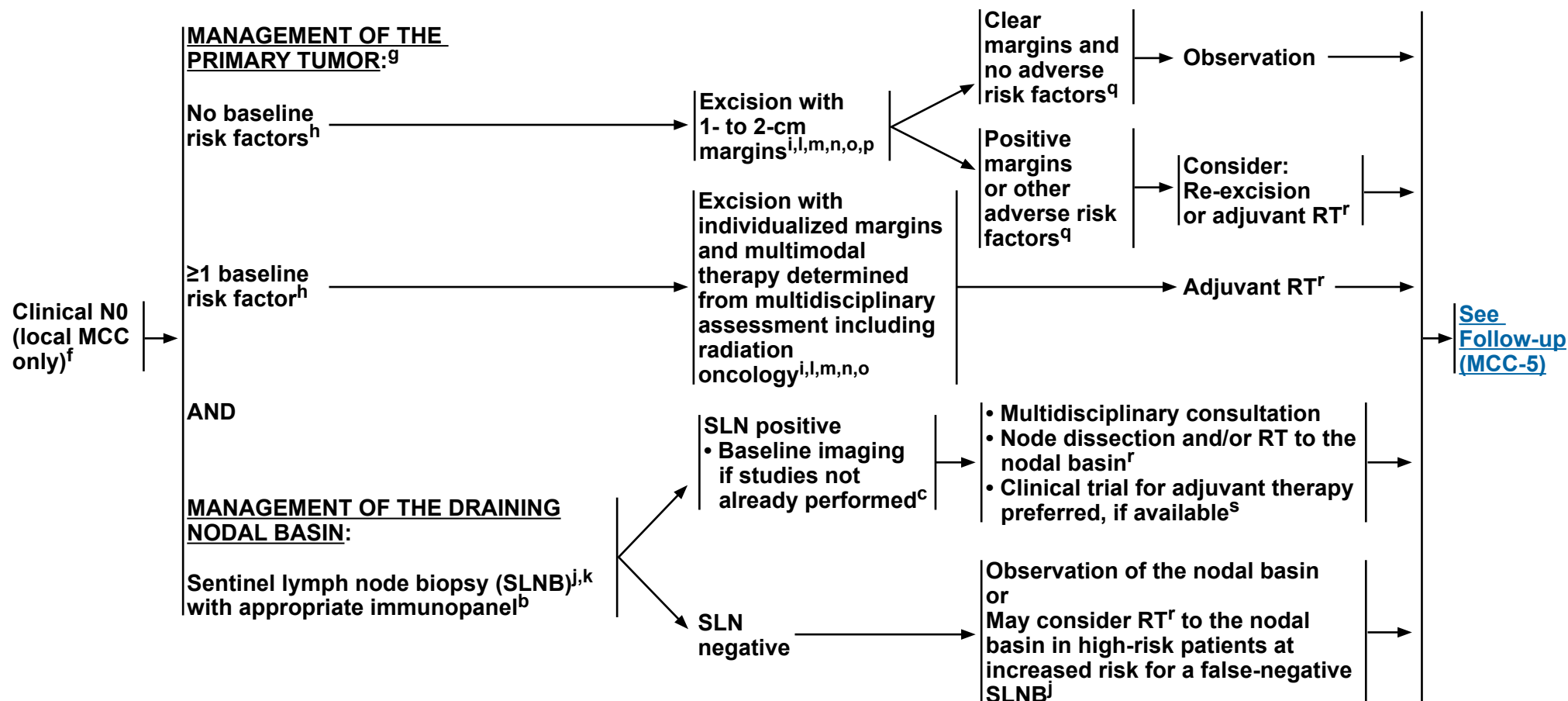
^e As immunosuppression in MCC is a risk factor for poor outcomes, immunosuppressive treatments should be minimized as clinically feasible in consultation with the relevant managing physician. As immunosuppressed patients are at high risk for recurrence, more frequent follow-up may be indicated.

Note: All recommendations are category 2A unless otherwise indicated.

Clinical Trials: NCCN believes that the best management of any patient with cancer is in a clinical trial. Participation in clinical trials is especially encouraged.



PRIMARY AND ADJUVANT TREATMENT OF CLINICAL N0 DISEASE



[See Footnotes on MCC-2A](#)

Note: All recommendations are category 2A unless otherwise indicated.
Clinical Trials: NCCN believes that the best management of any patient with cancer is in a clinical trial. Participation in clinical trials is especially encouraged.



FOOTNOTES

^b [See Principles of Pathology \(MCC-A\).](#)

^c Imaging is encouraged in most cases of MCC. Imaging is indicated whenever metastatic or unresectable disease is suspected based on H&P findings. Occult metastatic disease that resulted in upstaging has been detected in 12%–20% of patients presenting without suspicious H&P findings (Singh N, et al. J Am Acad Dermatol 2021;84:330-339). Whole-body PET with fused axial imaging (CT or MR) or chest/abdomen/pelvis CT with contrast, with neck CT if primary tumor on head/neck or brain MRI if clinical suspicion, may be useful to identify and quantify regional and distant metastases. Several studies indicate whole-body PET with fused axial imaging is more sensitive for detecting occult metastatic disease at baseline. Imaging may also be useful to evaluate for the possibility of a skin metastasis from a noncutaneous primary neuroendocrine carcinoma (eg, small cell lung cancer), especially in cases where CK20 is negative. The most reliable staging tool to identify subclinical nodal disease is SLNB. (George A, et al. Nucl Med Commun 2014;35:282-290; Hawryluk EB, et al. J Am Acad Dermatol 2013;68:592-599; Siva S, et al. J Nucl Med 2013;54:1223-1229).

^f Criteria for "Local MCC only" are disease limited to the primary tumor, with no evidence of in-transit, nodal, or distant disease.

^g Tarabdar E, et al. J Am Acad Dermatol 2021;84:340-347.

^h Baseline risk factors: larger primary tumor (>1 cm); chronic T-cell immunosuppression, HIV, CLL, solid organ transplant; head/neck primary site; lymphovascular invasion present.

ⁱ [See Principles of Excision \(MCC-C\).](#) In selected cases in which complete surgical excision is not possible, surgery is refused by the patient, or surgery would result in significant morbidity, radiation monotherapy may be considered. [See Principles of Radiation Therapy \(MCC-B\).](#)

^j Consider empiric radiation therapy (RT) to the nodal basin when: 1) the accuracy of SLNB may have been subject to anatomic compromise (lymphoma involved nodes, or history of remote lymph node excision); 2) when the risk of false-negative SLNB is high due to aberrant lymph node drainage and presence of multiple SLN basins (such as in head & neck or midline trunk MCC); or 3) when identified by lymphoscintigraphy in cases of profound immunosuppression (ie, solid organ transplant recipients). [See Principles of Radiation Therapy \(MCC-B\).](#)

^k SLNB is an important staging tool. This procedure and subsequent treatment impacts regional control for patients with positive SLNs, but the impact of SLNB on overall survival is unclear.

^l SLNB is typically performed at this time.

^m Narrow excision margins minimize morbidity and microscopically positive margins are acceptable when followed by adjuvant RT to the primary site.

ⁿ Mohs or other forms of peripheral and deep en face margin assessment (PDEMA), using margins similar to wide local excision (WLE), may be appropriate. [See NCCN Guidelines for Squamous Cell Skin Cancer - Principles of PDEMA Technique](#) for description of PDEMA.

^o Surgical margins should be balanced with morbidity of surgery. If appropriate, avoid undue delay in proceeding to RT. [See Principles of Excision \(MCC-C\).](#)

^p Goal should be primary tissue closure to allow for initiation of adjuvant RT (if needed) within 3–4 weeks.

^q Post-excision adverse risk factors include positive or narrowly clear margins, or lymphovascular invasion or positive SLNB.

^r [See Principles of Radiation Therapy \(MCC-B\).](#)

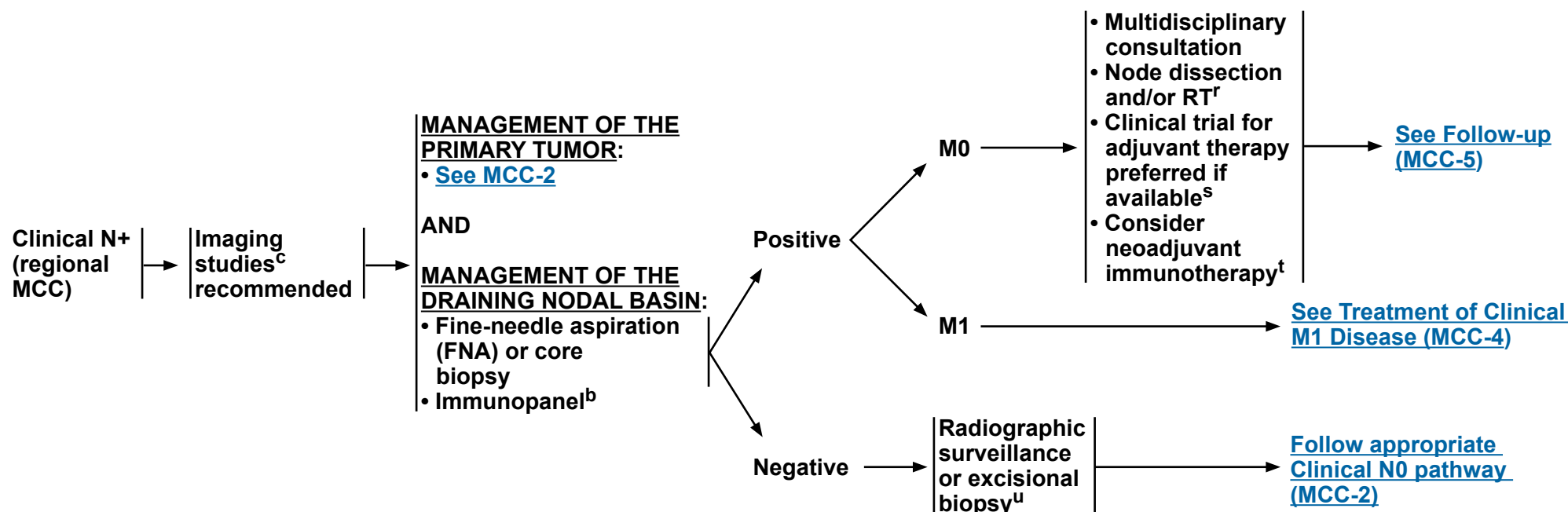
^s Adjuvant chemotherapy may be considered in select clinical circumstances; however, available retrospective studies do not suggest survival benefit for adjuvant chemotherapy. No data are available to support the adjuvant use of immunotherapy outside of a clinical trial. [See Principles of Systemic Therapy \(MCC-D\).](#)

Note: All recommendations are category 2A unless otherwise indicated.

Clinical Trials: NCCN believes that the best management of any patient with cancer is in a clinical trial. Participation in clinical trials is especially encouraged.



PRIMARY AND ADJUVANT TREATMENT OF CLINICAL N+ DISEASE



^b [See Principles of Pathology \(MCC-A\)](#).

^c Imaging is encouraged in most cases of MCC. Imaging is indicated whenever metastatic or unresectable disease is suspected based on H&P findings. Occult metastatic disease that resulted in upstaging has been detected in 12%–20% of patients presenting without suspicious H&P findings (Singh N, et al. J Am Acad Dermatol 2021;84:330-339). Whole-body PET with fused axial imaging (CT or MR) or chest/abdomen/pelvis CT with contrast, with neck CT if primary tumor on head/neck or brain MRI if clinical suspicion, may be useful to identify and quantify regional and distant metastases. Several studies indicate whole-body PET with fused axial imaging is more sensitive for detecting occult metastatic disease at baseline. Imaging may also be useful to evaluate for the possibility of a skin metastasis from a noncutaneous primary neuroendocrine carcinoma (eg, small cell lung cancer), especially in cases where CK20 is negative. The most reliable staging tool to identify subclinical nodal disease is SLNB. (George A, et al. Nucl Med Commun 2014;35:282-290; Hawryluk EB, et al. J Am Acad Dermatol 2013;68:592-599; Siva S, et al. J Nucl Med 2013;54:1223-1229).

^r [See Principles of Radiation Therapy \(MCC-B\)](#).

^s Adjuvant chemotherapy may be considered in select clinical circumstances; however, available retrospective studies do not suggest survival benefit for adjuvant chemotherapy. No data are available to support the adjuvant use of immunotherapy outside of a clinical trial. [See Principles of Systemic Therapy \(MCC-D\)](#).

^t [See Principles of Systemic Therapy \(MCC-D\)](#).

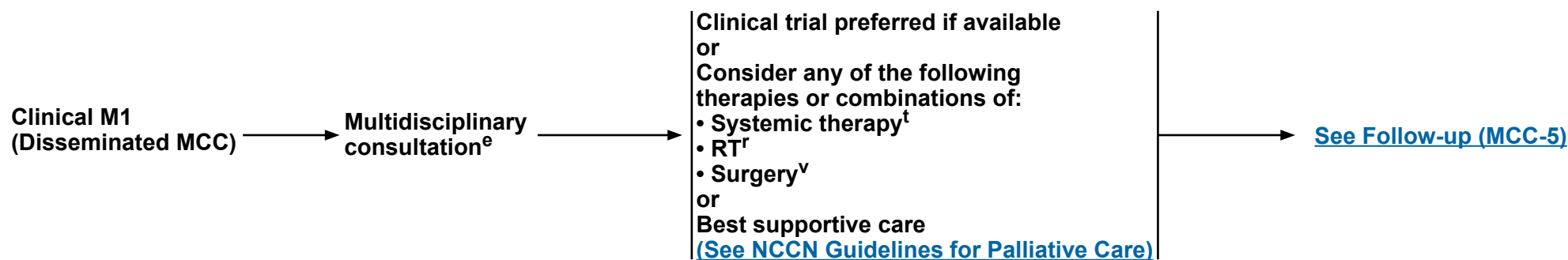
^u An open biopsy may be considered to confirm a negative initial FNA or core lymph node biopsy if clinical suspicion remains high.

Note: All recommendations are category 2A unless otherwise indicated.

Clinical Trials: NCCN believes that the best management of any patient with cancer is in a clinical trial. Participation in clinical trials is especially encouraged.



TREATMENT OF CLINICAL M1 DISEASE



^e As immunosuppression in MCC is a risk factor for poor outcomes, immunosuppressive treatments should be minimized as clinically feasible in consultation with the relevant managing physician. As immunosuppressed patients are at high risk for recurrence, more frequent follow-up may be indicated.

^r [See Principles of Radiation Therapy \(MCC-B\).](#)

^t [See Principles of Systemic Therapy \(MCC-D\).](#)

^v Under highly selective circumstances, in the context of multidisciplinary consultation, resection of limited metastases can be considered.

Note: All recommendations are category 2A unless otherwise indicated.

Clinical Trials: NCCN believes that the best management of any patient with cancer is in a clinical trial. Participation in clinical trials is especially encouraged.



FOLLOW-UP

RECURRENCE

TREATMENT

Follow-up visits:^e

- Physical exam including complete skin and complete lymph node exam
 - ▶ Every 3–6 mo for 3 years
 - ▶ Every 6–12 mo thereafter
- Imaging and other studies as clinically indicated^{c,d,v}
 - ▶ Consider routine imaging for high-risk patients^w

Recurrence

Local and/or
Regional

Disseminated^u

Clinical trial preferred if available
or
Consider any of the following
therapies or combinations of:
• Systemic therapy^t
• RT^r
• Surgery^v
or
Best supportive care
([See NCCN Guidelines for Palliative Care](#))

[See Clinical M1 \(MCC-4\)](#)

^c Imaging is encouraged in most cases of MCC. Imaging is indicated whenever metastatic or unresectable disease is suspected based on H&P findings. Occult metastatic disease that resulted in upstaging has been detected in 12%–20% of patients presenting without suspicious H&P findings (Singh N, et al. J Am Acad Dermatol 2021;84:330-339). Whole-body PET with fused axial imaging (CT or MR) or chest/abdomen/pelvis CT with contrast, with neck CT if primary tumor on head/neck or brain MRI if clinical suspicion, may be useful to identify and quantify regional and distant metastases. Several studies indicate whole-body PET with fused axial imaging is more sensitive for detecting occult metastatic disease at baseline. Imaging may also be useful to evaluate for the possibility of a skin metastasis from a noncutaneous primary neuroendocrine carcinoma (eg, small cell lung cancer), especially in cases where CK20 is negative. The most reliable staging tool to identify subclinical nodal disease is SLNB. (George A, et al. Nucl Med Commun 2014;35:282-290; Hawryluk EB, et al. J Am Acad Dermatol 2013;68:592-599; Siva S, et al. J Nucl Med 2013;54:1223-1229).

^d Quantitation of serum MCPyV oncoprotein antibodies may be considered as part of initial workup; seronegative patients may have a higher risk of recurrence; in seropositive patients, a rising titer may be an early indicator of recurrence; baseline testing should be performed within 3 months of treatment, because titers are expected to decrease significantly after clinically evident disease is eliminated.

^e As immunosuppression in MCC is a risk factor for poor outcomes, immunosuppressive treatments should be minimized as clinically feasible in consultation with the relevant managing physician. As immunosuppressed patients are at high risk for recurrence, more frequent follow-up may be indicated.

^r [See Principles of Radiation Therapy \(MCC-B\).](#)

^t [See Principles of Systemic Therapy \(MCC-D\).](#)

^u Under highly selective circumstances, in the context of multidisciplinary consultation, resection of limited metastases can be considered.

^v Surveillance imaging is typically via diagnostic CT of chest/abdomen/pelvis with oral and IV contrast; neck CT is often included if primary lesion was on head/neck.

^w Patients at high risk of recurrence include those who are immunosuppressed and patients who have positive non-SLN metastases.

Note: All recommendations are category 2A unless otherwise indicated.

Clinical Trials: NCCN believes that the best management of any patient with cancer is in a clinical trial. Participation in clinical trials is especially encouraged.



PRINCIPLES OF PATHOLOGY

- Pathologists should be experienced in distinguishing MCC from cutaneous simulants and metastatic tumors.
- Synoptic reporting is preferred.
- Minimal elements to be reported include largest tumor diameter (cm), peripheral and deep margin status, lymphovascular invasion (LVI), and extracutaneous extension (ie, bone, muscle, fascia, cartilage).
- Strongly encourage reporting of these additional clinically relevant factors (compatible with the American Joint Committee on Cancer [AJCC] and the College of American Pathologists [CAP] recommendations):
 - ▶ Depth (Breslow, in mm)
 - ▶ Tumor-infiltrating lymphocytes (not identified, brisk, non-brisk)
 - ▶ Tumor growth pattern (nodular or infiltrative)
 - ▶ Presence of a second malignancy within the pathologic specimen itself (ie, concurrent squamous cell carcinoma [SCC])
- Immunohistochemistry should be used for confirmation on all newly diagnosed MCC to exclude possible mimickers such as metastatic small cell carcinoma. Staining with CK20 (membranous and/or paranuclear dot-like) and negativity for thyroid transcription factor-1 (TTF-1) are usually sufficient. If an atypical staining pattern is present, AE1/3 keratin (dot-like), or at least one neuroendocrine marker (such as synaptophysin, neurofilament, chromogranin, CD56, or neuron-specific enolase [NSE]), and/or Merkel cell polyomavirus T antigen (CM2B4) stains may be employed.
- For equivocal lesions, consider additional immunostaining with neuroendocrine markers such as chromogranin, synaptophysin, CD56, NSE, and neurofilament.
- SLNB evaluation for metastatic MCC requires complete microscopic evaluation of the SLN(s). Before determining SLNB negativity, multiple levels (recommend at least 2) including H&E and at least one immunohistochemistry stain should be used to help evaluate for metastatic disease. SLNB reporting should also include the number of lymph nodes involved, size of largest metastatic deposit (mm), and the presence/absence of extracapsular extension.

Note: All recommendations are category 2A unless otherwise indicated.

Clinical Trials: NCCN believes that the best management of any patient with cancer is in a clinical trial. Participation in clinical trials is especially encouraged.



PRINCIPLES OF RADIATION THERAPY

General Principles

- **Expeditious initiation of adjuvant radiation therapy (RT) after surgery is preferred as soon as wound healing permits, as delay has been associated with worse outcomes.**
- **There is limited evidence supporting dosing recommendations for MCC. Dose ranges provided are based on clinical practice at NCCN Member Institutions and clinical evidence from studies of other types of skin cancer.**

General Treatment Information—Primary MCC Tumor Site

- **Treatment Information**
 - ▶ **Bolus is used to achieve adequate skin dose. Wide margins (5 cm) should be used, if possible, around the primary site. If electron beam is used, an energy and prescription isodose should be chosen that will deliver adequate dose to the lateral and deep margins.**
- **General Dosing Prescription**
 - ▶ **All doses are at 2 Gy/day standard fractionation.**
 - ▶ **In the palliative setting, a wide range of fractionation schedules may be used, including less protracted fractionation schedules such as 30 Gy in 10 fractions, 20 Gy in 4 or 5 fractions, or 8 Gy in 1 fraction.**

Following Resection of Primary MCC

Dose Recommendations

Adjuvant RT

Negative resection margins	50–56 Gy
Microscopically positive resection margins	56–60 Gy
Grossly positive resection margins and further resection not possible	60–66 Gy

No Previous Resection of Primary MCC

Dose Recommendations

Unresectable	60–66 Gy
Surgery refused by patient	60–66 Gy
Surgery would result in significant morbidity	60–66 Gy

Note: All recommendations are category 2A unless otherwise indicated.

Clinical Trials: NCCN believes that the best management of any patient with cancer is in a clinical trial. Participation in clinical trials is especially encouraged.

**PRINCIPLES OF RADIATION THERAPY****General Treatment Information—Draining Nodal Basin****• Treatment Information**

- ▶ Irradiation of in-transit lymphatics is recommended only when the primary site is in close proximity to the nodal bed.

• General Dosing Prescription

- ▶ All doses are at 2 Gy/day standard fractionation.
- ▶ In the palliative setting, a wide range of fractionation schedules may be used, including less protracted fractionation schedules such as 30 Gy in 10 fractions, 20 Gy in 4 or 5 fractions, or 8 Gy in 1 fraction.

	<u>Dose Recommendations</u>
No SLNB or LN dissection	
Clinically evident lymphadenopathy	60–66 Gy^{1,2}
Clinically node negative, but at risk for subclinical disease	46–50 Gy
SLNB without LN dissection	
SLN negative — RT not routinely indicated ³	Observation
SLN positive ⁴	50–56 Gy
After LN dissection with multiple involved nodes and/or extracapsular extension⁵	50–60 Gy

¹ Lymph node dissection is the recommended initial therapy for clinically evident adenopathy, followed by postoperative RT if indicated.

² Shrinking field technique.

³ Consider empiric RT to the nodal basin when: 1) the accuracy of SLNB may have been subject to anatomic compromise (lymphoma involved nodes, or history of remote lymph node excision); 2) when the risk of false-negative SLNB is high due to aberrant lymph node drainage and presence of multiple SLN basins (such as in head & neck or midline trunk MCC); or 3) when identified by lymphoscintigraphy in cases of profound immunosuppression (ie, solid organ transplant recipients).

⁴ Microscopic nodal disease (SLN positive) is defined as nodal involvement that is neither clinically palpable nor abnormal by imaging criteria, and microscopically consists of small metastatic foci without extracapsular extension.

⁵ Adjuvant RT following lymph node dissection is only indicated for multiple involved nodes and/or the presence of extracapsular extension. Adjuvant RT following LN dissection is generally not indicated for patients with low tumor burden on SLNB or with a single macroscopic clinically detected lymph node without extracapsular extension.

Note: All recommendations are category 2A unless otherwise indicated.

Clinical Trials: NCCN believes that the best management of any patient with cancer is in a clinical trial. Participation in clinical trials is especially encouraged.



PRINCIPLES OF EXCISION

Goals:

- Obtain histologically negative margins when clinically feasible.
- Surgical margins should be balanced with morbidity of surgery.

Surgical Approaches:

- It is recommended, regardless of the surgical approach, that every effort be made to coordinate surgical management such that SLNB is performed at the time of definitive excision.¹ Excision options include:
 - ▶ If adjuvant RT is planned, narrow excision margins are likely sufficient. ([See MCC-2](#))
 - ▶ If adjuvant RT may not be indicated ([See MCC-2](#)), perform wide excision with 1- to 2-cm margins to investing fascia of muscle or pericranium when clinically feasible and consistent with reconstruction and radiation goals listed below.
 - ▶ Techniques for more exhaustive histologic margin assessment may be considered (Mohs or other forms of PDEMA),² provided they do not interfere with SLNB when indicated.
 - ▶ If SLNB is not performed concurrently, it is recommended that SLNB is performed prior to definitive excision with exhaustive histologic margin assessment (ie, Mohs).

Reconstruction:

- It is recommended that any reconstruction involving extensive undermining or tissue movement be delayed until negative histologic margins are verified and SLNB is performed if indicated.
- Since RT is often indicated postoperatively, closure should be chosen to allow for expeditious initiation of RT (eg, primary closure, avoiding extensive tissue movement).

¹ SLNB is an important staging tool. This procedure and subsequent treatment impacts regional control for patients with positive SLNs, but the impact of SLNB on overall survival is unclear.

² When Mohs is being performed and the preoperative biopsy is considered insufficient for providing all the staging information required to properly treat the tumor, submission of the central specimen for vertical paraffin-embedded permanent sections or documentation of staging parameters in Mohs report is recommended.

Note: All recommendations are category 2A unless otherwise indicated.

Clinical Trials: NCCN believes that the best management of any patient with cancer is in a clinical trial. Participation in clinical trials is especially encouraged.



PRINCIPLES OF SYSTEMIC THERAPY¹

Local Disease N0:

- For primary disease, adjuvant chemotherapy is not recommended.
- Recurrent locally advanced
 - Consider pembrolizumab^{2,3} if curative surgery and curative RT are not feasible.⁴

Regional Disease N+:

- Clinical trial (preferred)
- For regional disease, adjuvant chemotherapy is not routinely recommended as survival benefit has not been demonstrated in available retrospective studies, but could be used on a case-by-case basis if clinical judgment dictates. No data are available to support the adjuvant use of immunotherapy outside of a clinical trial.
- Options useful in certain circumstances:
 - Neoadjuvant nivolumab^{3,5}
 - Cisplatin ± etoposide
 - Carboplatin ± etoposide
- For recurrent regional disease, consider pembrolizumab^{2,3} if curative surgery and curative RT are not feasible.⁴

Disseminated Disease M1:

- Clinical trial (preferred)
- Preferred interventions:
 - Avelumab^{2,3}
 - Pembrolizumab^{2,3,4}
 - Nivolumab^{2,3}
- Useful in certain circumstances as clinical judgment dictates for patients with contraindications to checkpoint immunotherapy:
 - Cisplatin ± etoposide
 - Carboplatin ± etoposide
 - Topotecan
 - Cyclophosphamide, doxorubicin (or epirubicin), and vincristine (CAV)

¹ When available and clinically appropriate, enrollment in a clinical trial is recommended. The literature is not directive regarding the specific chemotherapeutic agent(s) offering superior outcomes, but the literature does provide evidence that MCC is chemosensitive, although the responses are not durable, and the agents listed above have been used with some success.

² Data from non-randomized trials in patients with MCC demonstrate that rates of durable response are improved with PD-1/PD-L1 blockade compared with cytotoxic therapy. The safety profiles for checkpoint immunotherapies are significantly different from cytotoxic therapies. Consult prescribing information for recommendations on detection and management of immune-related adverse events associated with checkpoint immunotherapies. Clinician and patient education is critical for safe administration of checkpoint immunotherapies.

³ See [NCCN Guidelines for Management of Immunotherapy-Related Toxicities](#).

⁴ Nghiem P, Bhatia S, Lipson EJ, et al. Durable tumor regression and overall survival in patients with advanced Merkel cell carcinoma receiving pembrolizumab as first-line therapy. *J Clin Oncol* 2019;37:693-702.

⁵ Topalian SL, Bhatia S, Amin A, et al. Neoadjuvant nivolumab for patients with resectable Merkel cell carcinoma in the CheckMate 358 Trial. *J Clin Oncol* 2020;38:2476-2487.

Note: All recommendations are category 2A unless otherwise indicated.

Clinical Trials: NCCN believes that the best management of any patient with cancer is in a clinical trial. Participation in clinical trials is especially encouraged.



American Joint Committee on Cancer (AJCC) TNM Staging Classification for Merkel Cell Carcinoma (8th ed., 2017)

Table 1. Definitions for T, N, M

T Primary Tumor

- TX** Primary tumor cannot be assessed (e.g., curetted)
- T0** No evidence of primary tumor
- Tis** *In situ* primary tumor
- T1** Maximum clinical tumor diameter ≤2 cm
- T2** Maximum clinical tumor diameter >2 but ≤5 cm
- T3** Maximum clinical tumor diameter >5 cm
- T4** Primary tumor invades fascia, muscle, cartilage, or bone

Clinical (N)

N Regional Lymph Nodes

- NX** Regional lymph nodes cannot be clinically assessed (e.g., previously removed for another reason, or because of body habitus)
- N0** No regional lymph node metastasis detected on clinical and/or radiologic examination
- N1** Metastasis in regional lymph node(s)
- N2** In-transit metastasis (discontinuous from primary tumor; located between primary tumor and draining regional nodal basin, or distal to the primary tumor) *without* lymph node metastasis
- N3** In-transit metastasis (discontinuous from primary tumor; located between primary tumor and draining regional nodal basin, or distal to the primary tumor) *with* lymph node metastasis

Pathological (pN)

pN Regional Lymph Nodes

- pNX** Regional lymph nodes cannot be assessed (e.g., previously removed for another reason or *not* removed for pathological evaluation)
- pN0** No regional lymph node metastasis detected on pathological evaluation
- pN1** Metastasis in regional lymph node(s)
- pN1a(sn)** Clinically occult regional lymph node metastasis identified only by sentinel lymph node biopsy
- pN1a** Clinically occult regional lymph node metastasis following lymph node dissection
- pN1b** Clinically and/or radiologically detected regional lymph node metastasis, microscopically confirmed
- pN2** In-transit metastasis (discontinuous from primary tumor; located between primary tumor and draining regional nodal basin, or distal to the primary tumor) *without* lymph node metastasis
- pN3** In-transit metastasis (discontinuous from primary tumor; located between primary tumor and draining regional nodal basin, or distal to the primary tumor) *with* lymph node metastasis

Clinical (M)

M Distant Metastasis

- M0** No distant metastasis detected on clinical and/or radiologic examination
- M1** Distant metastasis detected on clinical and/or radiologic examination
- M1a** Metastasis to distant skin, distant subcutaneous tissue, or distant lymph node(s)
- M1b** Metastasis to lung
- M1c** Metastasis to all other visceral sites

Pathological (M)

M Distant Metastasis

- M0** No distant metastasis detected on clinical and/or radiologic examination
- pM1** Distant metastasis microscopically confirmed
- pM1a** Metastasis to distant skin, distant subcutaneous tissue, or distant lymph node(s), microscopically confirmed
- pM1b** Metastasis to lung, microscopically confirmed
- pM1c** Metastasis to all other distant sites, microscopically confirmed

Used with permission of the American College of Surgeons, Chicago, Illinois. The original source for this information is the AJCC Cancer Staging Manual, Eighth Edition (2017) published by Springer International Publishing.

[Continued](#)



American Joint Committee on Cancer (AJCC)
AJCC Prognostic Stage Groups for Merkel Cell Carcinoma
(8th ed., 2017)

Table 2. AJCC Prognostic Groups

Clinical (cTNM)

	T	N	M
Stage 0	Tis	N0	M0
Stage I	T1	N0	M0
Stage IIA	T2-T3	N0	M0
Stage IIB	T4	N0	M0
Stage III	T0-T4	N1-3	M0
Stage IV	T0-T4	Any N	M1

Pathological (pTNM)

	T	N	M
Stage 0	Tis	N0	M0
Stage I	T1	N0	M0
Stage IIA	T2-T3	N0	M0
Stage IIB	T4	N0	M0
Stage IIIA	T1-T4	N1a(sn) or N1a	M0
	T0	N1b	M0
Stage IIIB	T1-T4	N1b-3	M0
Stage IV	T0-T4	Any N	M1

Used with permission of the American College of Surgeons, Chicago, Illinois. The original source for this information is the AJCC Cancer Staging Manual, Eighth Edition (2017) published by Springer International Publishing.



NCCN Categories of Evidence and Consensus

Category 1	Based upon high-level evidence, there is uniform NCCN consensus that the intervention is appropriate.
Category 2A	Based upon lower-level evidence, there is uniform NCCN consensus that the intervention is appropriate.
Category 2B	Based upon lower-level evidence, there is NCCN consensus that the intervention is appropriate.
Category 3	Based upon any level of evidence, there is major NCCN disagreement that the intervention is appropriate.

All recommendations are category 2A unless otherwise indicated.

NCCN Categories of Preference

Preferred intervention	Interventions that are based on superior efficacy, safety, and evidence; and, when appropriate, affordability.
Other recommended intervention	Other interventions that may be somewhat less efficacious, more toxic, or based on less mature data; or significantly less affordable for similar outcomes.
Useful in certain circumstances	Other interventions that may be used for selected patient populations (defined with recommendation).

All recommendations are considered appropriate.



NCCN Guidelines Version 1.2022

Merkel Cell Carcinoma

Discussion

This discussion corresponds to the NCCN Guidelines for Merkel Cell Carcinoma. Last updated: June 15, 2018.

Table of Contents

Overview	MS-2	NCCN Recommendations for Adjuvant Radiation Dosing and Administration	MS-23
Risk Factors for MCC	MS-2	NCCN Recommendations for Treatment of Distant Metastatic Disease	MS-24
MCPyV	MS-2	Systemic Therapy as Active Treatment for Metastatic or Unresectable Disease	MS-24
Literature Search Criteria and Guidelines Update Methodology	MS-3	Chemotherapy	MS-24
Diagnosis and Workup	MS-3	Immunotherapy	MS-24
Characteristics and Differential Diagnosis	MS-3	NCCN Recommendations for Selection of Systemic Therapy for Distant Metastatic Disease	MS-26
Pathology Report	MS-4	Follow-up and Recurrence	MS-26
NCCN Recommendations for Diagnosis and Pathology Report	MS-8	Patterns of Recurrence and Metastases	MS-26
Imaging	MS-9	Imaging Surveillance	MS-27
Staging and Initial Treatment	MS-12	Risk of Developing Secondary Cancers During Follow-up	MS-27
Nodal Staging	MS-13	NCCN Recommendations for Follow-up	MS-27
Clinically Node-Negative Disease: NCCN Recommendations for Further Workup	MS-14	Treatment of Recurrence	MS-28
Clinically Node-Positive Disease: NCCN Recommendations for Further Workup	MS-15	References	MS-29
Initial Management of the Primary Tumor	MS-15		
Initial Management of Regional Disease	MS-18		
Postoperative Radiation and Chemotherapy for Locoregional Disease	MS-19		
Postoperative Radiation	MS-19		
Postoperative Systemic Therapy	MS-21		
NCCN Recommendations for Postoperative Management of the Primary Tumor	MS-22		
NCCN Recommendations for Management of the Draining Nodal Basin	MS-22		
NCCN Recommendations for Clinically Node-Negative Disease	MS-22		
NCCN Recommendations for Clinically Node-Positive Disease Confirmed by FNA or Core Biopsy	MS-23		



NCCN Guidelines Version 1.2022

Merkel Cell Carcinoma

Overview

Merkel cell carcinoma (MCC) is a cutaneous neuroendocrine neoplasia formerly called *trabecular carcinoma*. Although rare, with approximately 2,488 cases per year diagnosed in the United States,¹ MCC is one of the most aggressive skin cancers, and its incidence is dramatically increasing.²⁻¹⁰ Population-based studies have found that the incidence of MCC started to rise in the early 1990s and is increasing 5% to 10% per year, about 2.5-fold over 10 years, 3-fold over 15 years, and 5.4-fold over 18 years.^{2,4-6,11} As MCC tumors are frequently misdiagnosed,¹²⁻¹⁶ part of the apparent increase in incidence may be due to the discovery of biomarkers that improve detection of the disease.¹⁷ MCC can grow rapidly and metastasize early,¹⁸ with 63% of primary lesions having grown rapidly in the 3 months prior to diagnosis,¹⁴ 26% to 36% presenting with lymph node involvement, and 6% to 16% presenting with distant metastatic disease according to U.S. studies.^{2,17,19-22} Large meta-analyses have shown that at least half of patients with MCC develop lymph node metastases and nearly one third develop distant metastases.²³⁻²⁶ Smaller but more recent studies have reported similar or higher rates of regional and distant metastases.²⁷⁻²⁹ Several large studies (n > 100) document the development of recurrence in 25% to 50% of all cases of MCC.^{5,15,18,25,26,30} MCC has a high mortality rate exceeding melanoma. The 5-year relative or MCC-specific survival rates range from 41% to 77%^{3,5-7,17,19,22,30,31} and depend on stage at presentation.^{5-7,15,17,19-22,26,30,32-34}

Risk Factors for MCC

Sun exposure is believed to be a major risk factor for MCC, based on increased incidence in geographical areas with higher UV (ultraviolet) indices;^{17,35,36} increased incidence in patients with extensive prior UVA (ultraviolet-A) photochemotherapy;³⁷ the tendency to occur on areas of the skin that are exposed to the sun (81%), such as the head and neck (29%–48% of all primary MCCs);^{15,17,19,20,25,26,30,33,35,38,39} and the frequency of MCCs comingled or adjacent to other skin lesions caused by UV

exposure.^{13,16,40-42} Recent genetic analyses have found much higher mutational burden in Merkel cell polyomavirus (MCPyV)-negative tumors, and have also found that only the MCPyV-negative group are enriched for cytosine to thymine (C to T) mutations indicative of UV damage.⁴³⁻⁴⁵ MCC incidence increases with age and is more likely to occur in Caucasians compared with other ethnicities.^{2,4,6,17,19,35} In the United States, most patients with MCC are elderly (at least 90% are >50 years, >76% are ≥65 years, and >49% are ≥75 years)^{14,17,19,20,22,39} and nearly all are Caucasian (≥95%).^{7,14,15,19,20,22,33,35} MCC is disproportionately more common in immunosuppressed individuals, such as those with organ transplants, lymphoproliferative malignancies (such as chronic lymphocytic leukemia [CLL]), or HIV infections.^{14,32,36,46-49} Several studies have reported that MCC-specific survival is worse for those with immunosuppression,^{15,33,50,51} although other studies have found no correlation.^{38,52}

MCPyV

In 2008, Feng et al⁵³ identified MCPyV, a novel polyomavirus in MCC tumor tissues. MCPyV was detected in 43% to 100% of patient tumors.⁵⁴⁻⁵⁷ Several groups have explored the significance of antibodies to MCPyV in patients with MCC.⁵⁸⁻⁶⁰ In one prospective validation study that included 219 patients with newly diagnosed MCC, quantitation of MCPyV oncoprotein antibodies (present in about half of MCC patients at diagnosis) was performed to assess the utility of these antibodies for determining prognosis and for early detection of disease recurrence.⁵⁷ This study found that baseline oncoprotein antibody determination may be useful as part of initial workup. In this study, patients who were oncoprotein antibody seronegative at diagnosis had significantly (42%) higher risk of recurrence, suggesting that they may benefit from more intensive surveillance.⁵⁷ This study also found that for seropositive patients, the oncoprotein antibody test may be a useful component of ongoing surveillance because a rising titer can be an early indicator of recurrence.⁵⁷

**Literature Search Criteria and Guidelines Update Methodology**

The NCCN Non-Melanoma Skin Cancer Panel has developed guidelines outlining treatment of MCC to supplement the squamous cell and basal cell skin cancer guidelines (see [NCCN Guidelines for Basal Cell Skin Cancer](#) and [NCCN Guidelines for Squamous Cell Skin Cancer](#)). MCC is a rare tumor; therefore, prospective, statistically significant data are lacking to verify the validity of prognostic features or treatment outcomes. The panel relied on trends that are documented in smaller individual studies, in meta-analyses, and in their own collective experiences.

For each update of the NCCN Guidelines for Merkel Cell Carcinoma, an electronic search of the PubMed database was performed to obtain key literature using the following search terms: (merkel AND cell AND [carcinoma OR cancer OR malignancy OR lesion OR tumor]). The search results were narrowed by selecting studies in adult patients published in English. Articles were also excluded if they: 1) involved investigational agents that have not yet received FDA approval; 2) did not pertain to the disease site; 3) were clinical trial protocols; or 4) were reviews that were not systematic reviews. The search results were further narrowed by selecting publications reporting clinical data, meta-analyses and systematic reviews of clinical studies, and treatment guidelines developed by other organizations. The potential relevance of the PubMed search results were examined by the oncology scientist and panel chair, and a list of selected articles was sent to the panel for their review and discussion at the panel meeting. The panel also reviewed and discussed published materials referenced in Institutional Review Comments or provided with Submission Requests. The Discussion section was developed based on review of data from peer-reviewed publications as well as articles from additional sources deemed as relevant to these guidelines and/or discussed by the panel (eg, e-publications ahead of print, meeting abstracts). Any recommendations for which high-level evidence is lacking

are based on the panel's review of lower-level evidence and expert opinion.

The complete details of the development and update of the NCCN Guidelines are available at www.NCCN.org.

Diagnosis and Workup**Characteristics and Differential Diagnosis**

The diagnosis of MCC is rarely clinically suspected because the primary tumor lacks distinguishing characteristic features and is often asymptomatic. A study of a cohort of 195 patients with pathologically confirmed MCC found that at presentation, 88% of MCC tumors were asymptomatic and correct clinical diagnosis was rare (only 1%).¹⁴ Based on clinical impression, 56% of MCC tumors were initially presumed to be benign cysts/lesions.¹⁴ Other studies have reported clinical misdiagnoses rates of at least 40%. They confirm that MCCs are commonly misdiagnosed as benign lesions or nonmelanoma skin cancers, but that they are also sometimes misdiagnosed as other rare malignant skin tumors.^{12,13,15,16,61} Misdiagnosis is even more prevalent among MCC tumors that are admixed or adjacent to other skin tumors.^{16,62}

MCC tumors visualized by hematoxylin and eosin (H&E) typically contain small round blue cells with sparse cytoplasm, abundant mitoses, and dense core granules in the cytoplasm.^{40,63-70} The histologic diagnosis may also be challenging because MCC is similar to a variety of other widely recognized small round blue cell tumors, including metastatic visceral neuroendocrine carcinomas (eg, neuroblastoma, rhabdomyosarcoma, metastatic carcinoid, desmoplastic small cell tumor, small cell or amelanocytic melanoma, mesenchymal chondrosarcoma, Ewing sarcoma, small cell lung cancer [SCLC], lymphomas, osteosarcoma).⁷¹⁻⁷⁶ The most difficult differentiation is often between primary MCC and metastatic small cell carcinoma of the lung.



NCCN Guidelines Version 1.2022

Merkel Cell Carcinoma

Immunohistochemistry (IHC) has proved useful for distinguishing MCC from other small round cell tumors. In one early study, MCC was correctly diagnosed by light microscopy in 56 of 93 cases (60%), but IHC or electron microscopy was needed to diagnose the remaining 37 cases.¹² Cytokeratin 20 (CK20) and thyroid transcription factor 1 (TTF-1) often provide the greatest sensitivity and specificity to exclude SCLC.^{66,77-86} CK20 is a very sensitive marker for MCC since it is positive in 75% to 100% of primary tumors and rarely positive in SCLC.^{66,75,79,81-84,86} TTF-1 is never positive in MCC, but is often positive in SCLC (>80%) and other primary pulmonary tumors and is sometimes positive in other types of small cell cancers.^{66,75,81-86} IHC for CK20 and most low-molecular-weight cytokeratin markers is typically positive with a paranuclear “dot-like” pattern.^{66,74,79,85,87-89} CK7 is expressed in >80% of SCLC, but it is less prevalent in MCC.^{75,87,90-92} Neuroendocrine markers such as chromogranin, synaptophysin, CD56, neuron-specific enolase (NSE), and neurofilament are found in most MCC tumors.^{13,65,66,76,93-97} Although the specificity of each of these for MCC is not high,^{13,40,64,74,75,91,98-100} when used together they can help identify MCC tumors that are CK20 negative or have other features that make them difficult to diagnose, such as tumors with squamous components or epidermotropism.^{90,101-106} Synaptophysin and chromogranin have been widely used to confirm MCC diagnosis,^{70,88,107-110} although a few studies have used other neuroendocrine markers.¹¹¹

Pathology Report

Synoptic Reporting

Both historically and currently, consistent synoptic reporting of histopathologic parameters for MCCs is not widespread. This is unfortunate because it significantly limits retrospective analysis assessing the diagnostic and prognostic value of specific parameters. For these reasons the AJCC strongly encourages synoptic reporting for MCC primary tumor specimens, including but not limited to the parameters

needed for determining T-stage.¹¹² The College of American Pathologists (CAP) provides a complete synoptic report protocol for cutaneous MCC.^{113,114}

Elements of Report

The following parameters are needed for determining AJCC T-stage for MCC: maximum tumor diameter and tumor extension (invasion of fascia, muscle, cartilage, or bone).¹¹² The AJCC recommends that maximum tumor diameter should be measured clinically before resection, because shrinkage of formalin-fixed tissue may lead to the underestimation of tumor diameter.¹¹² Pathologic analysis is needed to assess extracutaneous invasion of the primary tumor for the purposes of AJCC staging.¹¹² T-staging based on these 2 parameters is supported by analysis of 5-year overall survival (OS) of 6,127 patients with local MCC only (clinically and, if known, pathologically lymph node negative).²¹ Other analyses of large patient populations have also shown that primary tumor size^{20,22,38,115} and extracutaneous extension have prognostic value (see subsections below).¹¹⁶ Although not required for staging, AJCC strongly encourages synoptic reporting of primary tumor thickness, measured microscopically from the granular layer of the overlying epidermis to the deepest point of tumor invasion.¹¹²

In addition to primary tumor size (greatest dimension) and extracutaneous extension, the 2 features needed to assign AJCC T-stage, the CAP protocol for MCC pathology also includes the following primary tumor elements: site (if known), peripheral and deep margin status, and lymphovascular invasion (LVI).¹¹⁴ Optional CAP elements for the primary tumor include specimen laterality, tumor thickness, mitotic rate, infiltrating lymphocytes (present/absent, brisk/nonbrisk), growth pattern (nodular, infiltrative), and presence of second malignancy.¹¹⁴ The prognostic value of histopathologic features is a topic of much debate. As described below, an emerging body of literature suggests that these primary tumor features



may provide relevant prognostic information with regard to survival and/or sentinel lymph node (SLN) positivity in MCC.

Tumor Size (Diameter)

In addition to the analyses of National Cancer Database (NCDB) data that support T-staging criteria for the AJCC staging guidelines,^{19,21} many studies have analyzed the relationship between primary tumor size (diameter) and various outcomes—including lymph node involvement, ability of treatment to achieve local control, probability of distant metastasis, disease-specific survival (DSS), and OS. Whereas results from small studies (n < 400) are variable, with some finding significant associations between primary tumor size and outcomes^{5,30,38,52,117} and others not,^{15,30,33,51} analyses of large databases (N > 1000; eg, SEER, NCDB) have all found primary tumor size to have prognostic value.^{20,22,115,116,118} These large studies have found that tumor diameter is significantly associated with nodal involvement, DSS, and OS. It is important to note that even in studies showing significant association between primary tumor diameter and nodal status, the risk of microscopic lymph node involvement (clinical N0) is non-negligible even among patients in the smallest tumor size category (eg, 40%, 24%–26%, and 14% LN+ for diameter <2 cm, <1 cm, and <0.5 cm).^{22,38,118-120}

Extracutaneous Extension

The 8th edition of the AJCC Cancer Staging Manual includes primary tumor invasion of fascia, muscle, cartilage, or bone as the definition of stage T4 for MCC. This is supported by results from a single-institution study published in 2008 showing by univariate analysis that survival was inversely correlated with the deepest anatomic compartment invaded by the primary tumor (dermis, subcutaneous tissue, or deeper fascia and skeletal muscle).¹²¹ This correlation was significant both for the total population analyzed (including both patients with and without nodal/distant metastases, n = 156) and for patients with localized disease (no lymph

node or distant metastases, n = 111).¹²¹ Analysis of a large population of MCC cases from the NCDB found that tumor diameter was reasonably predictive of relative survival among patients with small primary tumors, but resulted in poor separation among patients with larger primary tumors (ie, >2 cm), even when only including patients with local disease (n = 1558).¹⁹ Addition of a new T-stage, T4, defined as primary tumor invasion of bone, muscle, fascia, or cartilage, provided better prognostic separation.¹⁹ An updated analysis of the NCDB confirmed that this definition of T4 provides reasonable separation in terms of survival.²¹ In addition, an analysis of a much larger database (SEER, n = 2104) found that tumor extension beyond the dermis was an independent prognostic factor for DSS.¹¹⁶

Peripheral and Deep Margin Status

Results vary between studies analyzing the prognostic value of margin status, with some studies showing correlations with local control, OS, or disease-specific death (DSD),^{30,31,34,51,115,122} but others finding no significant associations with outcome.^{6,123-128} The largest study looking at margin status in 6901 MCC cases in the NCDB showed that margin status was significantly associated with survival for patients with stage I, stage II, or stage III MCC.¹¹⁵ Varying results may be due to differences in surgical approach across or even within institutions, treatment received for “positive” margins, and the exact criteria used to determine margin status. One study of 179 cases found that margin status was correlated with local recurrence in patients who were treated with surgery alone, but was far less predictive among patients who received adjuvant radiation therapy (RT).³¹ Margin status is important to record for the purpose of generating data for future prognostic analyses, but also to help inform follow-up surveillance in the event that the patient does not receive adjuvant RT. For both peripheral and deep margins, the CAP protocol for MCC specifies that for margins uninvolved by carcinoma, the distance of carcinoma from the margin should be recorded in millimeters (mm).¹¹⁴ It also indicates that



the specific locations of uninvolved and involved margins be specified, if possible, beyond simply designating as “deep margin” or “peripheral margin.”¹¹⁴

Lymphovascular Invasion

Whereas a few small studies ($n < 100$) did not find angiolymphatic invasion to be significantly associated with SLN positivity (in clinical N0 patients),^{107,120,129} several studies from Memorial Sloan Kettering Cancer Center (MSKCC) with somewhat larger sample sizes ($n = 153$ – 412) have found LVI to be predictive of SLN positivity, recurrence, OS, and DSS.^{34,119,121,127} One Finnish study of 125 cases found LVI to be associated with larger tumor size, and also found a trend toward higher risk of metastatic disease and poorer survival.¹⁰⁸ Larger datasets are needed to determine whether LVI has independent prognostic value.

Tumor Thickness

Although among studies with small sample sizes ($n < 70$) analyses of the relationship between tumor thickness and outcomes have yielded inconsistent results,^{107,125,130-132} multiple institutions have now published studies with larger sample sizes ($n > 70$) showing correlation between tumor thickness or Breslow depth and SLN positivity, DFS, DSS, and OS.^{29,38,120,121,133} The statistical significance of these correlations varies, perhaps because primary tumor thickness may be correlated with primary tumor size.³⁸ Further research is needed to determine whether tumor thickness has independent prognostic value. Per the AJCC staging guidelines, tumor thickness should be measured as for Breslow thickness in cutaneous melanoma—as the microscopic distance from the granular layer of the overlying epidermis to the deepest point of tumor invasion—and recorded in mm.^{112,114}

Mitotic Index

A number of studies have attempted to determine whether mitotic index is prognostic in MCC; however, the results vary across institutions, with some showing correlations between mitotic activity and SLN positivity, DSS, or OS, albeit with varying levels of statistical significance,^{65,70,120,129,134} and others finding no significant association with metastasis, DSS, or OS.^{107,132} In addition to small sample size ($n < 140$), the variability of results may also be due to differences in assessment of mitotic rate, and may possibly be due to associations between mitotic rate and other prognostic factors. A few studies have suggested that mitotic rate in MCC tumors is correlated with tumor thickness, infiltrative growth pattern, and LVI.^{120,135} Reporting of mitotic rate using a standardized method is therefore important for generating data needed to determine the true prognostic value of this parameter. Per the CAP protocol, reporting mitotic index as number of mitotic figures per square mm is preferred to reporting the number per high-powered field (HPF), because the definition of HPF varies and depends on the technology available at the treating institution.¹¹⁴

Tumor Growth Pattern

A variety of terms have been used to describe the distinct growth patterns observed in MCC tumors.^{65,66,70,105,107,120,121,132,135-137} Whereas results from early studies were variable, possibly due to small sample sizes and differences in the number of growth pattern categories used,^{66,107} more studies with larger sample sizes ($n > 90$) showed that growth pattern is prognostic if tumors are grouped into one of two categories: 1) “nodular,” which includes tumors with growth pattern that may previously have been described as “circumscribed,” “solid,” “organoid,” “polypoid,” or “multinodular”; or 2) “infiltrative,” which includes growth patterns previously described as “diffuse” or “trabecular.”^{120,121} Per the CAP protocol, nodular pattern is defined as tumors with a relatively well-circumscribed interface with the surrounding tissue, typically composed of one or multiple



nodules.¹¹⁴ Infiltrative pattern is defined as tumors without a well-circumscribed interface, composed of single cells, rows, or trabeculae—strands of cells infiltrating through dermal collagen or deeper soft tissue.¹¹⁴ Low- and high-magnification images of tumors with these growth patterns can be found in Andea et al., 2008.¹²¹ Retrospective studies using these categories have found the infiltrative growth pattern to be associated with higher risk of SLN positivity or poor outcomes (death from MCC, development of metastases, poor OS),^{107,120,121} possibly due to the difficulty in fully excising tumors that are poorly circumscribed.

Tumor Infiltrating Lymphocytes

Whereas a few small studies (n < 30) did not find lymphocyte infiltration to be associated with improved outcomes,^{107,138} larger (n > 50) more recent studies from several institutions have found that the presence of infiltrating lymphocytes in MCC tumors was at least somewhat associated with improved outcomes (survival, DSS).^{121,133,139-142} There are many caveats to these findings, however. In some studies the association was significant in univariate but not multivariate analyses, for some outcomes but not others, or for the total population but not sub-analyses.^{66,121,133,139} Other studies found that the prognostic value of tumor-infiltrating lymphocytes (TILs) depends on the specific type of immune cells present; however, they disagree on which type of TILs have prognostic value.¹⁴⁰⁻¹⁴² Methods of identifying and quantifying TILs have varied across studies, which may account for some of the variability of results. The CAP protocol for MCC defines TILs as lymphocytes present at the interface of the tumor and stroma, without specifying any molecular markers.¹¹⁴ In the CAP protocol for MCC, the categories for TIL entry are based on the presence and distribution of lymphocytes in the tumor sample.¹¹⁴ TILs “not identified” includes samples in which lymphocytes are present but do not infiltrate the tumor. “Nonbrisk” is to be used when lymphocyte infiltration is focal or not present across the entire base of the vertical growth phase, and “brisk” is to be used for cases in which lymphocytes diffusely infiltrate the entire

base of the dermal tumor or the entire invasive component of the tumor.¹¹⁴ These two “brisk” TIL scenarios are illustrated with a schematic in the CAP protocol.¹¹⁴

Presence of Secondary Malignancy

Among patients diagnosed with MCC, many (up to 55%) have current or prior secondary malignancies.^{3,12,15,28,34,122,123,127,132,136,137,143-148} The proportion of patients with secondary malignancies is even higher in those with current/prior immunosuppression.^{149,150} The most common secondary malignancies in patients with MCC are other skin cancers (most often squamous cell carcinoma [SCC], but also basal cell carcinoma [BCC], melanoma, other rare skin cancers and precancerous conditions such as actinic keratosis), followed by leukemia or lymphoma, and then a variety of other solid malignancies.^{3,4,12,15,26,34,122,127,137,143,144,146,148} Large population-based analyses have shown that patients diagnosed with MCC are at higher risk of developing a second cancer, and that risk of the following cancers is significantly increased in patients with MCC: SCC, BCC, melanoma, CLL, non-Hodgkin's lymphomas (NHLs), and possibly lung, breast, and kidney cancers.^{32,147,148,151,152} Population-based analyses have also shown that risk of MCC is significantly higher in those who have been diagnosed with other cancers, particularly in those with SCC, BCC, melanoma, CLL, Hodgkin lymphoma, or NHL.^{32,151-153} A few studies found that patients with secondary malignancies had poorer survival than those with only MCC,^{15,133,144} although these findings were based on univariate analyses, and at least one of these studies found by multivariate analysis that secondary cancer was not a significant independent prognostic factor for survival,¹³³ and another of these analyses only included stage I-II cases.¹⁵ Currently there appears to be more data showing no significant association between previous, concurrent, or subsequent secondary malignancies and the likelihood of MCC SLN positivity (in those with clinically node-negative disease), lymph node metastasis, locoregional control (LRC), or survival.^{28,34,119,120,127,145,154} One study found that



NCCN Guidelines Version 1.2022

Merkel Cell Carcinoma

although prior/synchronous secondary malignancy was not significantly prognostic for recurrence, there was a significant association between prior/synchronous leukemia or lymphoma based on multivariate analysis.¹²⁷ This may, however, be due to risk associated with immunosuppression.

In addition to high rates of other cancers in patients with MCC, there are numerous reports of other malignancies or skin lesions found within or adjacent to MCC tumors.^{13,41,42,62,66,69,106,154-165} SCC is the most common type of malignancy found to be adjacent to or intermingled with MCC, and BCC, melanoma, actinic keratoses, Bowen's disease (BD), and neuroendocrine tumors are also often seen in close physical contact to MCC tumors.¹³ Many reports have described MCC tumors covered by an epidermal layer with features of BD or actinic keratoses, while others have described scattered malignant neuroendocrine cells within the epidermal or adnexal epithelium adjacent to an MCC tumor.^{13,40,65,69,90,102-104,133,163} Squamous or adnexal differentiation within the dermal component of MCC has also been frequently observed, often in tumors with adjacent epithelium containing scattered malignant neuroendocrine cells.^{13,42,65,102,103,107,133,163} In more recent literature MCC tumors with any of these non-MCC elements have been designated as having "combined" morphology/histology/phenotype. The frequency of the combined phenotype is unknown because estimates vary widely, ranging from <5% to >50%.^{13,40,42,65,66,105,107,133,154,165,166} This is likely due to small sample size (number of cases evaluated) and variation in methods used for histologic sampling and characterization. It is not known whether the "combined" phenotype is associated with poor outcomes, as there are very little comparative data available. One retrospective study compared 26 cases of combined/mixed phenotype with 20 cases of "pure" MCC, and found that patients with the combined tumors were more likely to have had prior nonmelanoma skin cancers, nonhematologic extracutaneous cancers, and immunosuppression/pro-inflammatory comorbidities, and tend to have

more metastasis, treatment failures, and death from disease.¹⁶ More consistent reporting of the presence of other types of lesions within or adjacent to MCC is needed to establish whether this is an independent risk factor for risk of progression and poor outcomes.

NCCN Recommendations for Diagnosis and Pathology Report

Initial workup of a suspicious lesion starts with a complete examination of the skin and lymph nodes followed by biopsy of the primary tumor. Initial diagnosis of MCC in the primary lesion by H&E staining should be confirmed by performing IHC staining. Because MCC is often misdiagnosed, diagnosis should be confirmed by a pathologist experienced in distinguishing MCC from cutaneous simulants and metastatic tumors. An appropriate immunopanel should include CK20 and TTF-1. Other IHC neuroendocrine markers such as chromogranin A, synaptophysin, neurofilament protein, NSE, and CD56 may be used in addition to CK20 and TTF-1 to exclude other diagnostic considerations.

The goals of the primary tumor excision specimen analysis are: 1) to accurately diagnose and distinguish the tumor from cutaneous simulants and metastatic tumors; 2) to provide complete pathologic tumor characteristics for staging according to recommended AJCC and CAP guidelines; and 3) to standardize pathologic data collection to further understand the critical biologic features that impact MCC behavior and prognosis. *Principles of Pathology* in the NCCN Guidelines algorithm outlines the elements that should be included in a pathology report. In accordance with the AJCC, the NCCN Panel agrees that synoptic reporting is preferred. At a minimum, the pathology report should include tumor size, peripheral and deep margin status, LVI, and extracutaneous extension to the bone, muscle fascia, or cartilage, as these features may prove to have prognostic value. The NCCN Panel strongly encourages reporting of the following additional primary tumor features: tumor thickness (Breslow, in mm), mitotic rate (#/mm² preferred, #/HPF, or MIB-1



index), tumor growth pattern (nodular or infiltrative), TILs (not identified, brisk, or non-brisk), and the presence of a second malignancy such as concurrent SCC within the pathologic specimen itself.

Imaging

The utility of imaging as part of baseline staging for MCC is an issue debated in the literature. A number of retrospective analyses have reported data on detection and appearance of MCC tumors using various imaging methods, including conventional x-ray,^{12,67,167} CT,^{12,167-170} ultrasound,^{12,170,171} MRI,^{67,167,170,171} scintigraphy,¹⁷²⁻¹⁷⁴ and PET or PET/CT.^{170,171,175-187} Among these imaging methods, those with the most reported data in patients with MCC are CT, MRI, and FDG PET or FDG PET/CT. For all 3 of these modalities there are reports showing detection of MCC primary tumors, lymph node metastases, and distant metastases found in a wide range of anatomic locations.^{12,67,167,168,171,176,177,179,183,187} Although ample evidence exists that these methods have identified MCC tumors in a variety of anatomic locations, this evidence alone does not necessarily imply that these imaging methods will detect all MCC tumors.

A number of studies have attempted to determine the utility of specific imaging methodologies for detecting MCC tumors, either in terms of the sensitivity, specificity, and positive/negative predictive value, or in terms of the number of patients who were upstaged or downstaged or had their management changed due to imaging findings.^{169-171,175-180,182-187} Many of these studies are limited by small sample size ($n < 30$),^{170,175-177,180,182,183,185,186} and did not consistently use pathologic confirmation as a standard of reference for determining whether imaging results were true or false positives or true or false negatives.^{169,170,175,177,183,186,187} Regarding the use of MRI for detection of MCC, data on the sensitivity, specificity, and impact on staging or management are very limited. For CT and PET/CT, however, these metrics have been calculated in multiple studies, as described in the following sections.

Computed Tomography

Only a few studies have evaluated the utility of CT (separately from other imaging modalities) for detection of MCC tumors.^{169,171} In one study of 35 patients with imaging and biopsy-proven MCC, Gupta et al¹⁶⁹ compared the results of baseline scans with the results of SLN biopsy (SLNB; when available), further radiologic tests, or clinical follow-up for 6 months. In this study, the calculated sensitivity of baseline imaging for detection of lymph node metastases was only 20%, with negative imaging results in 16 of 20 patients with regional disease.¹⁶⁹ A separate study compared CT results with pathology from SLNB or lymph node dissection (LND) in 69 patients.¹⁷¹ Whereas scans of LN basins correctly identified 15 patients with nodal involvement (15 true positives), and correctly identified 36 nodal basins without MCC (36 true negatives) with only one false positive, the sensitivity of CT for detecting LN metastases was low (47%) due to negative imaging results in 17 of 32 patients who were shown to have nodal disease based on SLNB or LND (17 false negatives).¹⁷¹ In this study CT imaging not only failed to detect micrometastases (<1 mm; $n = 6$ patients), but also larger lymph node metastases, including single node positivity in 6 patients and multiple positive nodes in 5 patients.¹⁷¹ To determine whether CT imaging may provide useful nodal staging information despite low sensitivity, results were analyzed for the subset of patients who had all 3 tests (imaging, clinical exam, and pathology from SLNB/LND; $n = 61$).¹⁷¹ Although CT and clinical exam results did not always agree, this analysis showed that CT did not provide any additional useful staging information because CT results supported incorrect restaging (compared with pathology) with the same frequency with which clinical exam resulted in incorrect restaging.

Gupta et al¹⁶⁹ also reported the results from 36 CT scans for the detection of distant metastatic disease. Although 4 of the suspicious findings were confirmed (4 true positives) and all 16 patients with negative results did not show any signs of progression within the first 6 months (16 true



negatives, 0 false negatives), there were 17 suspicious findings that did not progress during follow-up and were deemed false positives. The calculated specificity was 48%.¹⁶⁹ Thus, although CT imaging is widely used to screen for distant MCC metastases, data supporting the sensitivity and specificity of this approach are limited.

FDG PET/CT

Compared with CT imaging, there are many more studies on the utility of FDG PET/CT for detecting MCC tumors.^{170,171,175-180,183-187} In studies in which FDG PET/CT was compared with subsequent pathologic nodal evaluation (SLNB or LND), the calculated sensitivity of FDG PET/CT was markedly different across studies.^{171,179,185} Colgan et al¹⁷¹ retrospectively analyzed 33 patients who received whole-body FDG PET or FDG PET/CT prior to SLNB or LND. Imaging sensitivity was 83% based on correct identification of 10 of 12 positive lymph nodes (2 false negatives) and specificity was 95% based on correct identification of 20 of 21 disease-free lymph node basins (1 false positive). Whereas nodal disease was detected by clinical exam in 4 of 12 patients with positive nodal pathology, FDG PET or FDG PET/CT imaging identified 6 positive lymph node basins that were missed by clinical exam.¹⁷¹ In contrast, a retrospective analysis by Hawryluk et al,¹⁷⁹ including 36 patients who had FDG PET/CT before SLNB, found that FDG PET/CT detected nodal disease in only 3 of 21 patients (14%) who had positive SLNB results. Low sensitivity for detecting clinically occult lymph node metastases was also reported in a study by Liu et al¹⁸⁵ that included 16 patients who received FDG PET/CT prior to SLNB: FDG PET/CT detected regional disease in only 1 of 10 patients with positive SLNB results even though 8 patients were found to have measurable lymph node metastases (1–15 mm) by histologic analysis. The wide range of reported specificity may be due in part to differences in the extent of disease across the patient populations analyzed. The study by Hawryluk et al¹⁷⁹ included a high percentage of patients whose nodal disease was only detectable by IHC and thus

unlikely to be detected by FDG PET/CT. Another study of 18 patients with histologically proven MCC (including a wider range of stages) found that all MCC sites histologically proven to be >5 mm in diameter were detectable by FDG PET/CT.¹⁷⁶ This study, which was not limited to analysis of lymph node metastases, found that FDG PET/CT detected 13 of 14 histologically confirmed MCC tumors (sensitivity 94%).

Analyses using less stringent criteria for verifying imaging results (ie, allowing clinical or imaging follow-up as a standard for comparison) and that included a wide range of disease stages have reported overall sensitivity and specificity of FDG PET/CT for detecting MCC tumors ranging from 86% to 100% and 89% to 100%, respectively.^{170,175,177,181,183,188} Sources of FDG PET/CT false positivity (non-MCC–related FDG uptake excluded by clinical and histologic correlation) include nonspecific adenopathy, postoperative inflammation in tumor bed and LN basin, preexisting sarcoidosis, lung carcinoma, lymphoma, and newly diagnosed NHL.¹⁷⁹ A number of retrospective studies and one prospective study have reported that results from FDG PET/CT scans at initial presentation impacted baseline staging in 6% to 39% of patients and changed management in 6% to 37% of patients with MCC.^{178-180,183,188} Three of these studies included sample sizes of more than 50 patients.^{178,179,188} In a review of 102 patients by Siva et al,¹⁷⁸ FDG PET changed the stage and primary treatment (modality or intent) in 22% of patients, with 17% of patients upstaged due to the discovery of nodal or distant metastases and 5% downstaged. FDG PET results also altered the radiation technique or dose for another 15% of patients (change in management for 37% of patients).¹⁷⁸

Similar results were reported in another review of 97 patients by Hawryluk et al,¹⁷⁹ in which 16% of patients were upstaged by baseline FDG PET/CT scans. A prospective study of 58 patients imaged before treatment found that FDG PET results upstaged 26% of patients (no downstaging), and



altered management in 28% of patients (treatment modality, intent, extent, or dose).¹⁸⁸ It is important to note that for all of the abovementioned studies, FDG PET was only used in patients who presented with features indicating high risk of recurrence or clinical suspicion for nodal/distant spread. These data do *not* imply that all patients with MCC should be screened with FDG PET/CT at initial diagnosis. Most of the changes in stage and management based on FDG PET imaging results were due to discovery of more extensive lymph node involvement or distant metastatic disease, suggesting that FDG PET imaging may be more useful in patients with more (clinically) advanced disease at presentation. Indeed, several studies have reported average FDG PET maximum standardized uptake values (SUVmax) detected by FDG PET suggesting a possible trend toward higher uptake in MCC lymph node metastases compared with primary lesions, and a trend toward even higher uptake in non-lymph node metastases (eg, bone, liver, brain).^{176,179,187} Multiple studies assessing the utility of FDG PET/CT for MCC staging and surveillance have also reported identification of previously undetected secondary cancers, and some of these findings changed management.^{171,175-177,187}

Some evidence suggests that FDG PET/CT may be more useful than CT in detecting nodal and distant MCC. In the retrospective analyses by Colgan et al,¹⁷¹ in which CT and SLNB results were compared in 69 patients and FDG PET and SLNB results were compared in 33 patients, the calculated sensitivity of FDG PET was notably better than that for CT (83% vs. 47%). The upstaging results from the retrospective analysis by Siva et al¹⁷⁸ and from the prospective study by Poulsen et al¹⁸⁸ are particularly notable because in addition to clinical exam, the staging prior to FDG PET was based on CT of the draining nodal basin, and for the prospective study, CT of the chest and abdomen as well. Both of these studies found FDG PET/CT positive lymph nodes not detected by CT, and the latter also identified distant metastases not apparent on CT

scans.^{178,188} Hawryluk et al¹⁷⁹ also noted that FDG PET/CT identified bone metastases (n = 10) that were all not detected by CT.

The utility of FDG PET/CT is likely limited for identifying primary tumors in patients who present with nodal disease but no clinically apparent primary. In one study of patients who received a scan before primary excision, FDG PET/CT detected 41% (12/29) of clinically apparent primary tumors.¹⁷⁹ Nonetheless FDG PET/CT may be useful in patients with unknown primary tumors for the purpose of screening for clinically occult nodal and distant metastatic disease.

Detection of Distant Metastatic Disease

Many retrospective studies have reported on the pattern of MCC metastatic spread to distant sites, based on large patient databases that include data from various points in the development of the disease (diagnosis, assessment of response to treatment, restaging, follow-up, and sometimes postmortem).^{12,18,26,52,61,127,136,167,179,183,187,189} Based on these analyses, distant metastatic MCC is most likely to arise in distant lymph nodes or skin, bone/bone marrow, lung/pleura, or liver. The second tier of likely locations include the pancreas, adrenal glands, brain, kidneys, subcutaneous tissue, or muscle. Rarer sites of distant metastasis include the breast, gastrointestinal tract, testes, heart, retroperitoneum and peritoneal cavity, and a variety of other locations.

NCCN Recommendations for Imaging During Workup

For patients with biopsy-confirmed MCC, additional workup may include imaging studies as clinically indicated. Given that reports in the literature have found that even with FDG PET/CT, clinically occult lymph node metastases are not infrequently undetectable by imaging,^{171,179,185} the NCCN Panel does not generally recommend imaging for identifying subclinical or regional disease in patients who have no clinical signs of nodal spread. SLNB is considered the most reliable staging tool to identify subclinical nodal disease. Total body imaging is not routinely indicated, but



NCCN Guidelines Version 1.2022

Merkel Cell Carcinoma

is encouraged whenever metastatic or unresectable disease is suspected based on H&P findings. Specific examples of when imaging would be clinically indicated include presence of symptoms (eg, tender nodes) or abnormal lab results. Identification and imaging of palpable nodes is important, although size is not necessarily an indicator of node positivity, which is why pathologic evaluation of lymph nodes is more important. Imaging may be useful in identifying and quantifying distant metastases as clinically indicated due to the metastatic potential of this tumor. Imaging may also be indicated to evaluate for the possibility of a skin metastasis from a noncutaneous carcinoma (eg, small cell carcinoma of the lung), especially in cases where CK20 is negative, and to screen for secondary malignancies. Consultation with the surgical team is recommended, as surgeons may request imaging to better understand the anatomy of the disease for surgical planning.

Recommended imaging modalities include brain MRI with contrast and neck/chest/abdomen/pelvis CT with contrast or whole-body FDG PET/CT. FDG PET/CT scanning is widely used for diagnostic imaging of MCC and may be preferred in some instances, such as a primary tumor location on an extremity. CT or MRI with contrast may be used if whole-body FDG PET/CT is not available. Based on the pattern of metastases for MCC, whole-body FDG PET/CT or neck/chest/abdomen/pelvis CT is recommended when distant metastatic disease is suspected, but the use of brain MRI in this setting varies among NCCN Panel Members. Whereas some panel members prefer to include brain MRI when screening for distant metastatic disease in patients with nodal involvement, others reserve this test for cases that have an indication of brain metastases or in which widespread systemic disease has been detected.

Staging and Initial Treatment

After initial workup, treatment is primarily dependent on accurate histopathologic interpretation and on microstaging of the primary lesion. A

multidisciplinary panel is recommended to ensure high-quality coordinated care for patients diagnosed with this rare and challenging disease.¹⁹⁰

Surgery is the primary treatment modality for MCC, and it is needed for accurate microstaging of both the primary lesion and regional disease. However, there is some variability among individual clinicians and NCCN Member Institutions regarding the management of patients with MCC due to the absence of prospective clinical trials. Therefore, the MCC guidelines are suitably broad to reflect all the approaches taken by participating NCCN Member Institutions.

The current AJCC staging system (8th edition) is based on an updated analysis of 9,387 cases of MCC from the NCDB with a median follow-up of 28.2 months.²¹ The NCCN staging of MCC parallels the AJCC guidelines and divides presentation into local, regional, and disseminated disease.¹¹² The *Pathology Report* section describes the data supporting the primary tumor features relevant to determining T-stage, as well as additional features that the NCCN Panel recommends be included in characterization of the primary tumor. Clinical exam and initial imaging studies (if indicated) are used to make an initial determination of the clinical N-stage and M-stage, which in turn determines the recommended approach for evaluating pathologic nodal status. Although there is evidence that among patients with clinically apparent nodal disease at presentation, those with unknown primary have better outcome than those with synchronous known primary,^{21,33,191-193} and these findings are reflected in the AJCC staging system,¹¹² the NCCN recommendations for pathologic evaluation of nodal status and management of the nodal basin are the same for both of these groups of patients.



Nodal Staging

SLNB

Large retrospective analyses (n > 100) or meta-analyses of SLNB in patients with clinically node-negative localized MCC, have reported rates of SLN positivity ranging from 30% to 38%.^{15,38,137,169,194-197} As discussed in the sections on the elements of the pathology report, there are a number of primary tumor characteristics that have been proposed, although debated, to be predictive of SLN positivity, including primary tumor diameter, thickness, mitotic rate, anatomic location, LVI, and TILs.^{38,119,120,132,198} Nonetheless, despite many analyses of prognostic factors based on large patient samples, no low-risk category has been identified for which the rate of SLN positivity is negligible.^{38,119,120,198} Results from retrospective studies evaluating the prognostic value of SLN status have varied. Some studies showed significant association between SLN negativity and lower risk of recurrence^{169,194,198} and improved MCC-specific survival or OS.^{198,199}

Conversely, others findings show no significant prognostic value of SLN status,^{119,197} only nonsignificant trends toward improved outcomes in patients with negative SLNB results,³⁸ significant correlation between SLN status and some but not all outcomes,¹⁹⁵ or significant correlation with outcome only in the subpopulation that did not get adjuvant treatment to the nodal bed.¹⁹⁶ Variability in these results may in part be due to differences in application of SLNB techniques leading to differences in rates of successful identification of the SLN and differences in the rates of false-negative SLNB results. It may also be due to differences in treatment practices that impact the fraction of patients with negative SLNB results who nonetheless receive adjuvant treatment (eg, RT), as well as the fraction of patients with positive SLNB results who receive complete LND (CLND) and/or other adjuvant treatments. Reported rates of regional relapse in patients with negative SLNB results range from 5% to 12%, with corresponding false-negative rates between 17% and 21%.^{195,196,198} Some

studies have reported complicated drainage patterns for MCCs occurring in the head and neck, and many retrospective analyses have found that multiple SLNs were identified in some patients,^{185,195,196,198,200} suggesting that failure to identify all the relevant SLNs may have contributed to the relatively high rates of false-negative SLNB results.

Regarding the utility of SLNB for management of patients with clinically node-negative disease, another issue of debate is whether the SLNB procedure itself offers some protection against recurrence, progression, or death from disease. One retrospective study of patients with clinical stage I/II MCC found, by univariate and multivariate analysis, that the 474 patients who underwent SLNB had improved 5-year MCC-specific survival compared with the 719 patients who did not undergo SLNB (nodal observation only), although the actual difference in rates was small (79% vs. 74%).¹⁹⁹ Consistent with these findings, another multivariate analysis of a large population database (Kaiser Permanente Northern California) found that compared with patients who had no pathologic nodal evaluation (n = 129), those with SLNB alone (n = 26) or SLNB plus LND (n = 40) had lower risk of all-cause mortality, and that SLNB plus LND was also associated with improved MCC-specific mortality, although no significant association with locoregional recurrence rate was seen.³³ There is insufficient information in these large population-based databases to ascertain whether these apparent associations are due to the SLNB procedure itself or due to subsequent management choices informed by the results of pathologic nodal evaluation. Smaller retrospective studies using institutional databases with more complete patient data have found that among patients presenting with clinically node-negative MCC, SLNB is not significantly associated with improved LRC or OS,^{15,51} although one did report significantly longer OS for patients who underwent SLNB.²⁰¹



NCCN Guidelines Version 1.2022

Merkel Cell Carcinoma

SLNB Pathology

In patients with MCC, IHC analysis has been shown to be effective in detecting lymph node metastases not detected by H&E.^{179,202-204} Among the retrospective studies that included information about SLN histologic analysis in patients with MCC, most of those published in the past 10 years and a few published earlier included IHC with CK20 as part of routine screening.^{119,120,185,198,201-203,205-208} Some studies have also reported using other additional IHC stains for histologic analysis of SLNs, pancytokeratins (AE1/AE3, CAM5.2), and/or other antibodies sometimes used for differential diagnosis of primary MCC lesions, such as chromogranin A, TTF-1, neurofilament, and synaptophysin.^{119,120,185,198,201-203,206}

A detailed histologic analysis of SLN disease in 64 patients identified 5 patterns of MCC spread.²⁰⁹ The most common pattern (59% of cases) was a solid, sheet-like nodule detectable by H&E (IHC needed only for confirmation of MCC), and was associated with higher likelihood of extracapsular extension (ECE), identification of more than one positive lymph node, and the poorest outcomes (OS).²⁰⁹ The 4 other patterns described (patterns 2–5) were seen in lymph nodes with lower tumor burden, usually <200 tumor cells per LN. Three of these patterns were sometimes detectable by H&E alone but sometimes required IHC for detection. These 3 were described as “parafollicular” (nonsolid dispersed cells clustered in the parafollicular lymph node cortex), “sinusoidal” (variable numbers of isolated cells in the subcapsular and draining LN sinuses), and “perivascular hilar” (cells clustered around larger vessels in the LN hilum). The fifth pattern, seen in 16% of cases, was described as scattered single parenchymal tumor cells, and IHC was always required for detection.

Fine-needle Aspiration

Several retrospective studies have reported that fine-needle aspiration (FNA) biopsy, when analyzed using both cytomorphology and IHC to analyze the smears, is an accurate method for diagnosing MCC lesions, including primary tumors and nodal and distant metastases.^{207,210-212} One small study compared FNA results with subsequent LND results, and found that their ultrasound-guided FNA procedure identified all cases of LN metastases that were >6 mm, but did not consistently identify smaller foci.²⁰⁷ This finding underscores that FNA biopsy is not an appropriate method for detection of clinically occult metastases, but is effective for verifying MCC in palpable nodes. These studies provide detailed descriptions of cytomorphologic features seen in aspirate smears from MCC lesions.^{207,210-212} Common features include small-to-medium-sized malignant cells that are usually dispersed (discohesive single cells) but sometimes in small groups, and have round/oval shape, minimal cytoplasm, and nuclear moulding. Mitotic figures are often apparent. IHC analyses of FNA samples showed that most cases were positive for cytokeratin (CK20 positive in 88%–95%; AE1/AE3 positive in 10/10), often with dot-like paranuclear pattern.²¹⁰⁻²¹² Most cases were also positive for synaptophysin (73%–84%) and NSE (~85%), and nearly all cases were positive for CD56 (≥95%).²¹⁰⁻²¹² Chromogranin staining was present in a smaller proportion of cases (36%).^{211,212} In cases tested for markers for melanoma (S-100, HMB45, Melan A, CD45) or lymphoma (leukocyte common antigen [LCA]), results were nearly always negative.²¹⁰⁻²¹²

Clinically Node-Negative Disease: NCCN Recommendations for Further Workup

SLNB is considered the most reliable staging tool for identifying subclinical nodal extension. SLNB is recommended for all patients with clinically node-negative disease who are fit for surgery. Although very important for staging and for guiding treatment of MCC, the impact of SLNB on OS is unclear. Essentially all participating NCCN Member Institutions use the



NCCN Guidelines Version 1.2022

Merkel Cell Carcinoma

SLNB technique routinely for MCC. The NCCN Panel believes that by identifying patients with positive microscopic nodal disease and then performing full LNDs and/or RT, the care of regional disease in this patient population is maximized. SLNB should be performed prior to surgical removal of the primary, with special care taken in the head and neck region where drainage patterns are often complex and can lead to unreliable SLNB results (risk of false negatives). As for other skin cancers, SLNB is almost always performed at the time of initial surgical removal of the primary tumor.

In patients with MCC, IHC analysis should be included in the SLNB evaluation in addition to H&E sections to reduce risk of false negatives. CK20 immunostaining should be included in the pathologic assessment of SLNs evaluated for MCC to facilitate accurate identification of micrometastases. An appropriate immunopanel may also include pancytokeratins (AE1/AE3), depending on the immunostaining pattern of the primary tumor, and particularly if H&E sections are negative. Some NCCN Member Institutions routinely use both CK20 and pancytokeratin stains to evaluate SLN samples to ensure detection of MCC metastases because results from these 2 markers are not always consistent. The pathology report should also include the tumor burden of each node (% of node), tumor location (eg, subcapsular sinus, parenchyma), and the presence or absence of ECE.

Patients with positive SLNB results should receive baseline imaging, if not already performed, to screen for and quantify regional and distant metastases. Although for most patients imaging results will be negative, especially if there is low tumor burden in the sentinel node, it is important to confirm staging, and baseline scans are useful for comparison in the event of a suspected recurrence. Recommended imaging modalities for detecting regional or distant metastases are described in *NCCN Recommendations for Imaging During Workup* in this Discussion. If a

distant metastasis is detected, management should follow the M1 pathway.

Clinically Node-Positive Disease: NCCN Recommendations for Further Workup

A clinical N+ diagnosis (palpable lymph nodes) should be confirmed by using FNA or core biopsy with an appropriate immunopanel. Samples from palpable lymph nodes should be subjected to the same battery of tests recommended for SLN pathology (see *SLNB Pathology* in this Discussion). An open biopsy may be considered to confirm a negative initial FNA or core lymph node biopsy if clinical suspicion remains high. If negative results are confirmed, the patient should be managed as clinical N0. If initial or subsequent lymph node biopsy results are positive, imaging studies are recommended if not already performed to evaluate the extent of lymph node and/or visceral organ involvement. Recommended imaging modalities for detecting regional or distant metastases are described in *NCCN Recommendations for Imaging During Workup* in this Discussion. If a distant metastasis is detected, management should follow the M1 pathway.

Initial Management of the Primary Tumor

Surgery for the Primary Tumor

Given the potential for rapid growth and metastasis, surgery has been the most common approach used to treat primary MCC tumors. Retrospective studies have shown that patients who receive non-surgical primary treatment (due to patient choice, poor performance score, or other circumstances that render the patient a poor candidate for surgery) tend to have poorer outcomes than those initially treated with surgery.^{51,178,213} Outcomes for variety of surgical approaches to removal of MCC primary tumors have been reported in the literature, including a variety of biopsy approaches, either with or without subsequent re-excision to obtain clean margins, standard excision (with a range of margin sizes tested), local



NCCN Guidelines Version 1.2022

Merkel Cell Carcinoma

amputation, and Mohs micrographic surgery (MMS) or other approaches with integrated complete margin assessment.^{15,31,51,52,201,214-220}

As described in the *Pathology Report* section of this Discussion, entitled *Peripheral and Deep Margin Status*, results vary regarding the relationship between margin status (positive or negative) and local control, OS, or DSD. Whereas there are a number of retrospective studies that found that margin status (positive vs. negative) was associated with improved local recurrence and survival,^{31,34,51,115,214,218-221} other analyses did not consistently find significant association between margin status and outcomes (ie, recurrence, progression, survival).^{6,30,122-124,126-128,178,214,222-227}

This variability is likely due to postoperative RT to the primary site that at least partially reduces the risk of recurrence or progression associated with the presence of residual disease after surgery. Most of these studies included all stages of disease, or at least patients with locoregional disease, so the variable results regarding the relationship between margin status to outcomes may be due to other aspects of treatment (ie, choice of treatment for nodal and/or distant metastases) having a greater impact on outcome than margin status for the primary tumor. Among studies including patients with a range of disease stages, the apparent relevance of primary tumor margin status may also be related to the percent of the population who had nodal or distant metastases at presentation. Indeed, an analysis of 3 pooled prospective trials in patients receiving adjuvant RT for high-risk local or regional MCC found that pre-radiation margin status had no impact on time to locoregional failure.²²⁸ One retrospective study found that margin status was related with local recurrence rate only in those who did not receive postoperative RT to the primary site.³¹ Two other retrospective studies reported that among patients with stage I/II disease who were treated with surgery only (no RT or chemotherapy), local recurrence rate, overall recurrence rates, and OS were better for those with negative versus positive margins.^{214,221}

A number of retrospective studies have included patients a primary MCC treated with MMS or other surgical methods for ensuring histologically clear margins.^{15,51,201,215,218-220,229-233} In MCC, MMS may be used to ensure complete tumor removal and clear margins, while secondarily sparing surrounding healthy tissue.²³⁴ Consistent with results of some studies showing that negative margins may be correlated with better local control and survival, particularly for local disease treated with surgery alone, retrospective comparisons of MMS with other surgeries for primary MCC lesions have found that MMS was associated with improved outcomes compared with “standard excision” or biopsy,^{218,219,229} and in most studies MMS and wide local excision (WLE) resulted in similar rates of recurrence and survival.^{15,201,215,219,220,231} There are little data and much debate about the size of surgical excision margins needed to achieve histologically clear margins. A study of 45 patients with stage I MCC treated with MMS found that the mean margin of clinically normal skin needed to achieve histologic clearance was 16.7 mm, and that 2-cm and 3-cm surgical margins would have resulted in incomplete histologic clearance in 25% and 12% of patients, respectively.²³⁰ In contrast, a study of 196 patients with primary MCC treated with WLE found that 2-cm and 3-cm clinical margins resulted in incomplete excision in 50% and 0% of patients, respectively.²³⁵ Most recently, an analysis of 1795 patients in the NCDB who had primary MCC tumors found that WLE and MMS resulted in histologic margins in 3.7% and 4.9%, respectively.²²⁰ Among patients with histologically clear margins after WLE or MMS, there is a small amount of retrospective data suggesting a possible trend toward reduced risk of recurrence for patients with histologic margins >1 cm compared with 0.1 to 1 cm,^{31,201} but it is unlikely that increasing histologic margin size beyond 1 cm is associated with any additional clinical benefit.^{124,201,214}

Definitive Radiation Therapy for Locoregional Disease

Historically surgery has been the mainstay of treatment for local and regional MCC, with definitive RT used only for patients who are poor



candidates for surgery or who refuse surgical treatment. As a result, data on the efficacy of definitive RT for treatment of MCC is extremely limited. There are a large number of retrospective studies that include very small samples of patients ($n < 10$) who received definitive RT instead of surgery.^{27,30,34,51,61,123,124,126,143,191,224,225,227,236-247} As mentioned previously, there are several retrospective studies that found that patients who received nonsurgical initial treatment tended to have poorer outcomes than those initially treated with surgery.^{51,52,143,178,213,248} In these and other studies most of the patients not treated with surgery received definitive RT with or without chemotherapy; treatment with chemotherapy alone was rare and generally reserved for very advanced cases. The largest of these studies used data from MCC cases in the NCDB, comparing outcomes from 1227 patients treated with definitive RT (no surgery) with outcomes from 1227 patients treated with surgery (480 also had adjuvant RT) who were selected by propensity score matching based on age, Charlson-Deyo score (comorbidities), differentiation, and AJCC stage.²¹³ This analysis showed improved OS with surgery (\pm adjuvant RT) versus definitive RT (no surgery), both among patients with stage I/II (local) disease (median OS, 76 vs. 25 months; $P < .001$) and among those with stage III (locoregional) disease (median OS, 30 vs. 15 months; $P < .001$). Caveats to this analysis are that the patient population treated with surgery was more likely to have some factors that may be associated with improved outcomes: smaller size of primary tumor, primary tumor located in upper extremity, shorter time to diagnosis, treatment at an academic hospital, and no treatment with chemotherapy. Nonetheless, this study supports the notion that for patients with local or locoregional MCC, surgery as part of initial treatment likely provides better outcomes.

For those with local or locoregional MCC who are poor surgical candidates or refuse surgery, however, initial treatment that includes definitive RT likely provides better outcomes. One study using SEER data found that among patients with MCC who did not receive surgery ($n = 746$),

multivariate analysis showed that those who received RT had better OS and DSS (DSS at 5 years: 73% vs. 54%; $P < .0001$).²² Retrospective studies with more than 10 patients treated with definitive RT to their primary and/or nodal MCC, including both patients with no surgery and those with residual gross tumor after surgery, reported in-field recurrence rates less than 25%, with median time to in-field recurrence ranging from 4 to 6.3 months.^{31,236,249-253} One meta-analysis of 264 patients with locoregional MCC treated with definitive RT (from 23 studies) reported that cumulative in-field recurrence rate was 12% per site (of $n = 332$ irradiated sites), and that in-field recurrence was significantly more likely at regional versus primary irradiated sites (16% vs. 7.6%, $P = .02$).²⁴⁶

NCCN Recommendations for Initial Management of the Primary Tumor

Removal of the entire primary lesion with clear surgical margins is preferred, whenever possible, and can be achieved via any of the following methods. WLE with 1- to 2-cm margins to the investing fascia of muscle or pericranium should be performed when clinically feasible and with consideration of possible morbidity. Because of the high historic risk of local recurrence in MCC, the panel's tenets for surgical excision emphasize complete extirpation of tumor at the time of initial resection to achieve histologically clear surgical margins when clinically feasible. However, surgical margins should be balanced with morbidity of surgery, and should not be pursued to the degree of significantly delaying any planned adjuvant RT. Alternative methods for complete removal of the primary tumor include MMS, modified Mohs surgery, or excision with complete circumferential peripheral and deep margin assessment (CCPDMA), and may be considered provided that they do not interfere with SLNB, when indicated. The advantage of these alternative methods is that they ensure complete tumor removal and clear margins, while secondarily sparing surrounding healthy tissue. If MMS is used, the panel emphasized that a debulking specimen from the central portion of the



tumor should be sent for permanent vertical section microstaging. Modified MMS includes an additional permanent section for final margin assessment. In all cases, surgical management should be coordinated so that SLNB is performed prior to definitive surgery as surgery may alter lymphatic drainage. SLNB is usually performed intraoperatively during WLE.

As histologic margins may be obscured by extensive undermining or tissue movement, any major reconstruction involving extensive undermining should be delayed until verification of clear margins and SLNB is performed, if indicated. If adjuvant RT is planned, efforts should also be made to minimize delay to initiation of RT (eg, primary closure). If postoperative radiation is planned, significant tissue movement should be avoided as it may obscure the target area.

Radiation is acceptable for management of the primary tumor in select cases in which complete excision is not feasible or is refused by the patient. The recommended dose in these cases is 60 to 66 Gy. See *NCCN Recommendations for Adjuvant Radiation Dosing and Administration* in this Discussion.

Initial Management of Regional Disease

Because the presence of MCC in the lymph nodes is associated with poorer prognosis,^{5,21,30,51,110,116,122,123,141,218,222,224,227,239,247,248,254-258} the clinical instinct is to aggressively treat the nodal basin in the patient with (pathologically confirmed) positive lymph node(s). Indeed, a retrospective study of 87 patients with locoregional MCC (50 node-negative, 29 node-positive) found that nodal treatment was associated with improved disease control: LND prolonged the time to first recurrence (median of 11.8–28.5 months; $P = .034$ by multivariate analysis), as did RT to the nodal basin (median of 11.3–46.2 months; $P = .01$ by univariate analysis).¹²² A meta-analysis that included 39 patients with SLN positivity found that those who

received some form of post-SLNB treatment for nodal disease (therapeutic LND [TLND], RT, chemotherapy) had improved 3-year relapse-free survival (51% vs. 0%; $P < .01$).¹⁶⁹

Due to lack of prospective comparative data, however, it is unclear whether surgical approaches or radiation are more effective as initial treatment for nodal MCC. Although many MCC studies included patients with confirmed nodal disease, most did not report the outcomes according to the method or extent of initial nodal treatment, and many included too few patients to allow for meaningful multivariate analysis to examine the relationship between nodal treatment parameters and outcomes.^{12,15,28,30,33,34,51,97,110,127,128,146,149,188,197,199,214,222,226,241,243,244,255,257-263}

Focusing on studies with at least 20 patients with MCC lymph node involvement, there are a few retrospective analyses and meta-analyses that reported outcomes for specific nodal treatments.^{5,31,52,115,119,143,191,194,213,239,243,248,264} Of these studies, the 2 with the largest sample size, both using data from NCDB, reported conflicting results. As described above, Wright et al²¹³ included an analysis of 1473 stage III patients showing that surgery (with or without adjuvant RT) was associated with better OS compared with definitive RT (median 30 vs. 15 months, $P < .001$). In contrast, an analysis of 2065 patients with stage III MCC by Bhatia et al¹¹⁵ found no significant difference in OS for surgery alone compared with RT alone or compared with surgery plus RT, although surgical removal of 5 or more lymph nodes significantly improved survival (compared with removal of <5 nodes). For both of these studies a major caveat is the lack of detailed information about the extent of nodal disease before treatment, and the lack of information about the target (primary or nodal) and extent of RT and surgical approaches employed. Some of the smaller retrospective studies have more detail about the surgical and RT methods used, but nonetheless results are variable and unconvincing (for informing treatment selection) due to lack of statistical comparisons. Some of these studies suggest that nodal surgery may



improve outcomes,^{52,194,248,264} a few found that patients who received nodal RT (without surgery) fared better,^{5,31} and others found no clear trends according to nodal treatment,^{5,119,143,239} including a few with statistical analyses that found no significant differences in outcomes according to treatment modality.^{191,243}

There are very few data to inform the extent of nodal surgery needed for patients with biopsy-proven regional disease. Results from retrospective analyses suggest that MCC prognosis worsens with increasing nodal involvement, with higher risk of poor outcomes with clinically detectable nodal involvement versus microscopic nodal involvement,^{21,34,38,127} and increased risk of poor outcomes with increasing number of nodes involved^{22,30,115,116,118,197,209,225,241,253} and with the presence of ECE.^{29,197,241} These findings suggest that the aggressiveness of nodal treatment should perhaps be commensurate with the extent of nodal disease. Among patients treated with radical LND, CLND, or TLND, the likelihood of identifying one or more pathologically positive nodes depends on the indication for LND. As expected, rates are lower in patients with clinically occult sentinel nodes (cN0 with SLN+), with positive non-SLNs (NSLNs) found in 25% to 72% of patients,^{28,30,119,196,198,205,207,221,265} compared with patients with clinically detected nodal disease (cN+), of whom 60% to 100% have pathologically positive LNs.^{15,28,30,258}

The type of LN surgery may not be very important if patients are also treated with RT. A pooled analysis of several prospective studies found that the margin status of surgically removed lymph nodes was not associated with locoregional recurrence in patients who received radiation to the nodal basin.²²⁸ One of these prospective studies also found by multivariate analysis that among patients with locoregional MCC, all of whom were treated with surgery plus radiation (with or without chemotherapy), nodal involvement was not prognostic for DSS or OS.²⁶⁰

Postoperative Radiation and Chemotherapy for Locoregional Disease

Postoperative Radiation

Numerous retrospective studies and meta-analyses of data from retrospective studies have attempted to determine whether postoperative RT improves outcomes in patients with MCC. Some of these have found that postoperative RT is associated with improved freedom from recurrence and survival compared with surgery alone,^{3,26,122,126,145,198,218,256,259,266} others found no significant correlations with outcomes,^{15,30,196,208,267,268} and many reported mixed results, finding that adjuvant RT was significantly associated with improvements in some but not all outcome measures, and/or showing nonsignificant trends for some outcome measures.^{28,31,52,115,124,127,128,143,146,178,227,232,239,258,269,270} For most of these studies the results are difficult to interpret because the population included a range of MCC stages, a mix of primary and recurrent MCC cases, a variety of surgical procedures prior to RT (ie, mix of WLE and biopsy, negative and positive margins; SLND, CLND, or none), and a mix of patients who received RT to the primary site only, nodal basin only, or both. Therefore, it is unclear whether the differences in results across studies are due to differences in the patient population, treatment prior to RT, or details about the target site and RT dosing.

To try to assess the value of adjuvant RT in specific clinical contexts, some retrospective studies included subgroup analyses, although in many cases the small sample sizes of the subgroups precluded meaningful statistical analysis. A number of retrospective studies have focused on patients with locoregional disease (no distant metastases),^{52,126,127,239,258,270} including several large retrospective studies (n > 100) that used multivariate analysis to determine whether postoperative RT was correlated with outcomes in patients with locoregional disease.^{52,127,258,270} As for the larger population-based studies that included patients with distant metastatic disease, results of these analyses varied, with some



showing that the addition of RT reduced risk of recurrence and/or improved survival, while others found no significant association with these outcomes.^{52,127,258,270}

Data to inform decisions about adjuvant RT in more specific clinical contexts are far less abundant. Jouary et al²⁷¹ conducted the only randomized trial to date in MCC. Patients with stage I disease treated by wide excision and RT to the tumor bed were randomized to adjuvant regional RT or observation. The trial was closed prematurely due to a drop in recruitment attributed to the advent of SLN dissection. Analysis of 83 patients showed no improvement in progression-free survival (PFS) or OS with adjuvant radiation, but a significant decrease in risk of regional recurrence was found compared with the observation group (0% vs. 16.7%; $P = .007$). Aside from the randomized trial described, several retrospective studies have evaluated the association between adjuvant RT and outcomes in patients with node-negative disease.^{115,124,198,208,227,232,258,267} Unfortunately the results for both risk of recurrence/progression and survival (DSS or OS) are inconsistent, with some but not all studies showing improvements with postoperative RT.^{124,198,208,227,232,258,267} Therefore, it is not clear whether postoperative RT provides clinical benefit for patients with pathologically node-negative disease. It is important to note that for most of these studies adjuvant RT was sometimes administered to both the primary site and the nodal basin even in SLN-negative cases, and the impact of RT to the primary tumor bed versus the nodal basin was often not evaluated separately. The clinical value of RT to the primary tumor bed is unclear, because results are inconsistent among the studies in which patients with SLN-negative disease received RT to the primary bed only. In addition, results also vary across studies that evaluated RT to the primary tumor bed separately from RT to the nodal basin, with some finding that postoperative RT improves disease control and survival and others finding no statistically significant associations.^{31,128,198,258,261}

Several studies have attempted to determine whether clinical benefit from postoperative RT is associated with the size of the primary tumor, but results have varied across studies, with one finding that postoperative RT was associated with improved LRC and OS for all primary tumor size categories,²⁶⁸ but another finding that RT-associated improvement in survival was significant for some but not all primary tumor size categories.²⁵⁶ Several retrospective studies have tried to determine whether benefit from postoperative RT depended on margin status (after excision of the primary), but results did not agree.^{31,258} One retrospective study that focused specifically on very-low-risk stage I patients ($n = 46$)—defined as those with primary tumor size ≤ 2 cm, negative pathologic margins, negative SLNB, and no immunosuppression—found that adjuvant RT was associated with reduced risk of local recurrence (0% vs. 26%; $P = .02$) but had no impact on OS or DSS.²³² Therefore, despite all these analyses, it is still unclear how to identify patients with MCC most likely to benefit from postoperative RT.

Regarding the clinical benefit of RT for patients with node-positive MCC, results from retrospective analyses vary widely between studies.^{115,127,143,208,227,258} An NCDB analysis including 6908 patients found that adjuvant RT improved OS compared with surgery alone for patients with stage I or stage II MCC, but not for stage III disease.¹¹⁵ A retrospective study from UCLA ($n = 87$) had similar results, reporting that postoperative RT was associated with improved survival in patients with stage I/II disease, but not for the whole population (including all stages).²²⁷ In contrast, a retrospective study from Moffitt Cancer Center ($n = 171$) found that postoperative RT improved LRC and DSS in patients with pathologic or clinically positive nodes, but not in node-negative patients.²⁵⁸ A key difference between these studies is that while patients in the NCDB and UCLA study likely received a wide variety of surgical and RT interventions, patient selection in the Moffitt study was much more stringent, with most patients being treated with WLE with 1- to 2-cm



margins (n = 168/170), and all patients received pathologic nodal staging (SLNB for clinically node-negative patients, TLND for clinically node-positive patients).^{227, 115, 258} The results of the Moffitt study are noteworthy because LRC was improved by postoperative RT in patients with SLN-positive (clinically node-negative) disease (LRC, 3 years, for surgery alone vs. surgery plus RT: 27% vs. 76%; $P < .001$), even though more than half of these patients received CLND (n = 30/52), and in patients with pathologically confirmed clinical node-positive disease (LRC, 3 years: 0 vs. 75%; $P = .003$), even though all these patients had received TLND (n = 17/17).²⁵⁸

Postoperative Systemic Therapy

There are many studies that report outcomes for a small number of patients, but high-quality clinical data on adjuvant systemic therapy options for MCC are lacking, and almost all the data are for postoperative chemotherapy combined with radiation.^{272, 273} Most of the data are from retrospective studies, and assessment of efficacy is based on data pooled from patients with a range of stages, a variety of prior/concomitant therapies (eg, different types of prior surgery and prior or concurrent RT), and MCC treatment with a variety of systemic therapy agents and regimens. Even for the best available retrospective studies—those with the largest sample sizes and that use multivariate analyses to control for the many factors that may also impact outcome—the ability to assess the impact of postoperative systemic therapy on outcomes was often seriously limited by the fact that only a small minority of patients received chemotherapy. For most of the studies in which some subset of patients received postoperative chemotherapy, often in combination with adjuvant RT, use of chemotherapy was not associated with reduced risk of recurrence or distant metastasis, nor was chemotherapy associated with improved survival.^{27, 30, 33, 115, 128, 218, 223, 266, 268} One study found that adjuvant chemotherapy was associated with *worse* survival based on univariate analysis, but the association was not significant by multivariate analysis.²²³

Several studies found that postoperative chemoradiation did not improve outcomes compared with postoperative radiation,^{52, 218, 268} including one study in which results from a prospective trial of chemoradiation (carboplatin plus etoposide) in 40 patients with stage I-III disease were compared with historical controls (n = 62) treated with postoperative RT.²⁶⁰

A study of 4,815 patients with MCC in the NCDB that included 393 patients treated with surgery plus postoperative chemoradiation and 97 patients treated with surgery plus postoperative chemotherapy found by multivariate analysis that, relative to surgery alone, postoperative chemoradiation improved OS but postoperative chemotherapy (without radiation) had the opposite effect.²¹⁸ In a multivariate analysis of the subset of the 2,820 patients who received postoperative therapy, there was a nonsignificant trend toward improved OS with postoperative chemoradiation compared with postoperative RT alone ($P = .08$). However, this difference was significant in the subset of patients who had positive margins ($P = .03$) and in the subset with primary tumor size ≥ 3 cm ($P = .02$).²¹⁸ These results suggest that although postoperative chemotherapy without radiation is unlikely to improve outcomes, postoperative chemoradiation may have a role in particularly high-risk cases in which residual disease is present after surgery.

The most common systemic therapy regimen used for adjuvant treatment of regional disease is cisplatin or carboplatin with or without etoposide;^{27, 30, 52, 223, 260, 268} however, information about the agents used was not available from the NCDB analysis (described above) that showed that postoperative chemotherapy may provide clinical benefit in certain high-risk patients.²¹⁸ Although not routinely recommended for adjuvant treatment of regional disease, if used in select cases the panel recommends cisplatin or carboplatin with or without etoposide.



NCCN Recommendations for Postoperative Management of the Primary Tumor

After surgery, patients may undergo postoperative RT of the primary site or consider observation. The currently available clinical evidence on the efficacy of postoperative RT is inconsistent across studies, even for the lowest risk groups, so it is unclear how to identify candidates most likely to benefit from postoperative radiation of the primary tumor site. In the absence of clear consistent data regarding which patient- or disease-specific factors are associated with clinical benefit from postoperative RT, the panel suggests that observation may be reasonable for patients with small primary lesions (eg, <1 cm) that have been widely excised and who present with no adverse risk factors such as LVI or immunosuppression. LVI and immunosuppression are risk factors of particular concern because they are associated with a many-fold increased risk of recurrence or progression, at least in some studies.^{50,59,108,110,127,196,258,274} Associations with survival have been reported in some but not all studies evaluating the prognostic value of LVI^{29,34,108,122,129,133,178,257} and immunosuppression.^{15,33,38,51,52,59,110,139,142,198,244}

Adjuvant RT to the primary site is generally recommended for all other cases, especially for patients with microscopic or grossly positive margins or other risk factors for recurrence. Efforts should be made to avoid delay of adjuvant RT if planned, because delay between the time of surgery and RT initiation is associated with worse outcomes. Adjuvant RT dose to the primary site depends on the success of the prior surgery. Patients with negative resection margins are typically treated with 50 to 56 Gy, whereas higher doses are recommended for those with microscopically positive resection margins (56–60 Gy) or grossly positive resection margins in cases in which further resection is not possible (60–66 Gy).

Adjuvant chemotherapy is not recommended for local disease.

NCCN Recommendations for Management of the Draining Nodal Basin

NCCN Recommendations for Clinically Node-Negative Disease

As previously described, SLNB is recommended for all patients with clinical node-negative disease who are fit for surgery.

Treatment of the nodal basin in patients with a positive SLNB should be discussed in the context of a multidisciplinary consultation. Where available, clinical trial participation is the preferred choice for patients with positive SLNB. A multidisciplinary tumor board consultation is recommended to evaluate the treatment options. Most patients should undergo CLND and/or RT to the nodal basin. Adjuvant RT after LND is only indicated for patients with multiple involved nodes and/or the presence of ECE. Adjuvant RT after LND is generally not indicated for patients with low tumor burden on SLNB.

If SLNB results are negative, observation of the nodal basin is appropriate. Patients who are at high risk of disease progression may consider RT to the nodal basin. These include patients with profound immunosuppression and those with factors associated with increased risk of false-negative SLNB: operator or histologic failure (eg, failure to perform appropriate IHC on SLNs), anatomic features such as previous history of surgery including WLE, and location in the head and neck region, where risk is due to aberrant lymph node drainage and frequent presence of multiple SLN basins. Patients with immunosuppression include those with diseases such as CLL or HIV, and transplant recipients. Adjuvant chemotherapy is not recommended for patients with local disease.

If SLNB is not performed or is unsuccessful, RT to the nodal bed should be considered to treat subclinical disease.



NCCN Recommendations for Clinically Node-Positive Disease Confirmed by FNA or Core Biopsy

For patients with palpable lymph nodes confirmed by biopsy and imaging indicating that no distant metastases are present (M0), the panel recommends multidisciplinary tumor board consultation to consider the available treatment options for the positive lymph nodes and nodal basin. Preferences for treatment of nodal metastases vary across NCCN Member Institutions, but panel members agree that most patients should receive LND and/or primary RT. In most cases LND is the preferred approach for first-line treatment. Management of the primary tumor is the same as for patients with clinically node-negative disease.

NCCN Recommendations for Treatment After Lymph Node Dissection

Few data are available on which to base recommendations for adjuvant treatment after LND. Based on clinical practice in NCCN Member Institutions, RT is recommended after LND if ECE is detected or multiple nodes are involved. NCCN Panel Members are less likely to recommend adjuvant RT for patients for whom LND confirmed only a single positive lymph node without ECE. If adjuvant RT is planned after LND for multiple involved nodes and/or ECE, the recommended RT dose is 50 to 60 Gy.

Adjuvant systemic therapy is not routinely recommended because no survival benefit has been reported. Most NCCN Member Institutions only use systemic therapy for stage IV, distant metastatic disease (M1), with or without surgery and/or RT. A few NCCN Member Institutions suggest considering adjuvant systemic therapy for select cases of clinical (macroscopic) regional (N1b or N2) disease. However, available retrospective studies do not suggest that adjuvant chemotherapy provides survival benefit, and most institutions only use adjuvant chemotherapy for MCC in select cases.

For select patients for whom adjuvant systemic therapy is considered, treatment in the context of a clinical trial is preferred, when available. Trials testing adjuvant treatment with therapies that have been shown to be effective for unresectable and/or distant metastatic disease should be considered.^{275,276} Although available retrospective studies do not suggest prolonged survival benefit, if used in select patients, the panel recommends cisplatin or carboplatin with or without etoposide.

NCCN Recommendations for Adjuvant Radiation Dosing and Administration

The panel included radiation as an adjuvant treatment option for all stages of MCC. However, due to the lack of prospective trials with clearly defined patient cohorts and treatment protocols (eg, surgical margins prior to RT, location of radiation field), the dosing and administration recommendations are suitably broad to reflect all the approaches taken by participating NCCN Member Institutions. Ideally, adjuvant radiation is performed within 4 to 6 weeks after surgery, as delay may lead to negative outcomes; however, the NCCN recommendations do not include a specific timeframe. The panel recommends initiating RT as soon as possible after surgery.

Specifications for radiation dosing for primary and postoperative treatment of the primary site and draining lymph node basin are detailed in the algorithm under *Principles of Radiation Therapy*. Recommended doses depend on the extent of disease, with higher doses recommended for clinically apparent disease versus known/suspected subclinical disease versus no evidence of disease. Irradiation of in-transit lymphatics is often not feasible unless the primary site is in close proximity to the nodal bed.

When radiation is used for definitive or adjuvant treatment of the primary tumor site, doses should generally be delivered in 2 Gy/day standard fractionation, with bolus to achieve adequate skin dose. Wide margins (5



cm) around the primary site should be used if possible. If electron beam is used, an energy and prescription isodose should be chosen that will deliver adequate dose to the lateral and deep margins. If RT to the primary site is being used for palliation, a less protracted fractionation schedule may be used, such as 30 Gy in 10 fractions.

NCCN Recommendations for Treatment of Distant Metastatic Disease

The panel recommends multidisciplinary tumor board consultation for patients with distant metastatic disease (M1) to consider options for management. Comprehensive imaging is recommended for all patients with any clinically detected and pathologically proven regional or distant metastases.

In general, the management of patients with distant metastases must be individually tailored. Clinical trial is preferred if available, as little data are available to suggest the best approach for active treatment. The multidisciplinary panel may consider treatment with one or more of the following modalities: systemic therapy, radiation, and surgery. Systemic therapy and RT will likely be the primary treatment options to consider. Surgery may be beneficial in highly selective circumstances for resection of oligometastasis or symptomatic lesions. All patients should receive best supportive care, and depending on the extent of the disease and other case-specific circumstances, palliative care alone may be the most appropriate option for some patients.

Systemic Therapy as Active Treatment for Metastatic or Unresectable Disease

Chemotherapy

Responses to chemotherapy in patients with MCC have been reported for a variety of regimens, including regimens that contain platinum agents (often in combination with etoposide), cyclophosphamide (often in

combination with doxorubicin or epirubicin and vincristine; CAV), cyclophosphamide with methotrexate and 5-fluorouracil (CMF), paclitaxel, nab-paclitaxel, docetaxel, ifosfamide, anthracycline, 5-fluorouracil, topotecan, gemcitabine, irinotecan, and a variety of other agents.^{189,236,277-281} In analyses including more than 20 patients, reported overall response rates to chemotherapy for patients with MCC were usually around 40% to 60%, but in several studies the response rate appeared to depend on the number of prior chemotherapy regimens already attempted, with some studies reporting response rates up to 70% for first-line chemotherapy, and as low as 9% to 20% in patients who received one or more prior lines of chemotherapy.^{189,236,277-282} Reported responses to chemotherapy were fairly short-lived, with a median duration ranging from approximately 2 to 9 months.^{189,236,278-282} Reported rates of toxic death in patients receiving chemotherapy for MCC were between 3% and 10%, with elderly patients being at higher risk.^{189,236,278}

Immunotherapy

In addition to case reports of patients with MCC responding to checkpoint immunotherapies,²⁸³⁻²⁸⁸ phase I/II trials are currently evaluating response to avelumab, an anti-PD-L1 agent, and to the anti-PD-1 agents pembrolizumab and nivolumab, in patients with advanced MCC with measurable disease.²⁸⁹⁻²⁹³

A phase II, single-arm multicenter trial (NCT02267603) tested pembrolizumab in patients with either distant metastatic (n = 24) or recurrent locoregional (n = 2) MCC not amenable to definitive surgery or RT and no prior systemic treatment for unresectable disease.²⁹² After a median follow-up of 33 weeks (range, 7–53), the overall response rate for pembrolizumab was 56%. Further follow-up is needed to assess durability of response and PFS, although based on this early analysis response duration ranged from at least 2.2 months to at least 9.7 months.²⁹²



NCCN Guidelines Version 1.2022

Merkel Cell Carcinoma

The JAVELIN Merkel 200 trial (NCT02155647) is an open-label multicenter trial testing avelumab in patients with histologically confirmed and measurable stage IV distant MCC.^{289,291} In an interim analysis of patients with no prior systemic therapy for metastatic MCC (median follow-up, 5.1 months; range, 0.3–11.3 months), overall response rate to avelumab was 62% among those with at least 3 months follow-up (n = 29), and confirmed response rate was 71% among those with at least 6 months follow-up.²⁹¹ Further follow-up is needed to determine response duration, but the preliminary calculation of median PFS of 9.1 months appears promising compared with previously published retrospective analyses in which PFS after first-line chemotherapy ranged from 3 to 5 months.^{279,280} However, influence of chemotherapy on PFS could be negatively affected by the inherent biases of patient selection associated with retrospective studies.

The JAVELIN Merkel 200 trial also included a cohort of patients treated with avelumab after progression on one or more prior lines of systemic therapy.^{289,290} After a minimum 12-month follow-up (median, 16.4 months; range, 12.1–25.4), overall response rate was 33% in this cohort, and although follow-up was insufficient to determine median duration of response, an estimated 93% of responses will last at least 6 months and 74% will last at least 1 year.²⁹⁰ This response rate for avelumab is within the same range (9%–45%) reported in retrospective studies of patients who received second- or subsequent-line chemotherapy for MCC.^{189,279-281} However, retrospective analyses of patients with MCC treated with second- or subsequent-line chemotherapy report short-lived responses, with median duration of response ranging from 1.7 to 3.4 months.²⁷⁹⁻²⁸¹ For the cohort of patients in the JAVELIN Merkel 200 trial treated with avelumab for MCC refractory to previous lines of chemotherapy, median PFS was 2.7 months,²⁹⁰ which is within the same range (median 2–3 months) as reported in retrospective studies of patients receiving second-line or subsequent chemotherapy for MCC.²⁷⁹⁻²⁸¹ However, the Kaplan-

Meier PFS curve for avelumab appears to suggest that a notable fraction of the patients may experience long-term responses.²⁹⁰ Although the data need to mature, median OS was estimated to be 12.9 months for patients treated with avelumab as second-line or subsequent systemic therapy for MCC, and the Kaplan-Meier curve for OS appears to suggest that long-term survival may be possible.²⁹⁰ Previous retrospective studies reported median OS ranging from 4.4 to 5.7 months for patients with MCC treated with multiple lines of chemotherapy.²⁷⁹⁻²⁸¹

Results from the JAVELIN Merkel 200 trial led to FDA approval of avelumab for treatment of metastatic MCC. Although the label only includes data from the cohort of patients who received avelumab for previously treated metastatic disease, the FDA approved avelumab for *all* patients (aged 12 years or older) with metastatic MCC, regardless of treatment history.²⁹⁴ This indication was approved under accelerated approval based on response rate and duration of response, but continued approval may be contingent on results from confirmatory trials.

Preliminary results from the Checkmate 358 phase I/II trial that were reported in a conference abstract suggest that MCC is also sensitive to nivolumab.²⁹³ For 22 evaluable patients treated with nivolumab for MCC and measurable disease, ORR was 68% after a median follow-up of 26 weeks (range, 5–35 weeks).²⁹³ Although small sample sizes preclude meaningful statistical comparisons, ORR was slightly higher for patients without prior systemic treatment (n = 14) compared with those who had 1 or 2 prior systemic therapies (n = 8): 71% versus 63%.

Based on the preliminary analyses of phase I/II trials previously described, toxicity profiles in patients with MCC were similar for avelumab, pembrolizumab, and nivolumab, with treatment-related adverse events (AEs) occurring in 68% to 77% of patients, and grade 3 or 4 AEs occurring in 5% to 21%.^{289,291-293} Immune-related AEs were seen in <20% of patients receiving avelumab, and were all grade 1 or 2.^{289,291}



NCCN Guidelines Version 1.2022

Merkel Cell Carcinoma

NCCN Recommendations for Selection of Systemic Therapy for Distant Metastatic Disease

Clinicians should exercise independent medical judgment in choosing the systemic therapy regimen. Although the NCCN Panel recognized that MCC is a rare disease that precludes robust randomized studies, enrollment in clinical trials is encouraged whenever available and appropriate. Clinical trials testing therapies shown to be effective against other metastatic cancers (eg, melanoma) should be considered.²⁹⁵⁻²⁹⁹

Preliminary data demonstrate an early promising signal for anti-PD-L1 (avelumab) and anti-PD-1 (pembrolizumab, nivolumab) checkpoint immunotherapy in patients with metastatic MCC and measurable disease. Although there are no randomized comparative trials demonstrating superiority of checkpoint immunotherapy compared with chemotherapy, checkpoint immunotherapies provide response rates similar to those previously reported for chemotherapy, and may provide greater durability of response. Therefore, avelumab, nivolumab, and pembrolizumab are included as recommended systemic therapy options for treatment of disseminated disease, and use of cytotoxic therapies in this setting is discouraged unless the patient has contraindications to checkpoint immunotherapy or has experienced relapse or progression during or after previous treatment with checkpoint immunotherapy. Of these 3 checkpoint immunotherapies (avelumab, pembrolizumab, and nivolumab) recommended by NCCN as options for metastatic MCC, only avelumab has been FDA-approved for use in this setting.^{294,300,301}

The safety profiles for checkpoint immunotherapies are significantly different from cytotoxic therapies, so clinician and patient education is critical for safe administration of checkpoint immunotherapies. It is important to consult the prescribing information for recommendations regarding contraindications to checkpoint immunotherapy as well as the detection and management of immune-related AEs.^{294,300,301}

For patients with contraindications to checkpoint immunotherapy (including lack of durable response), cytotoxic therapies may be considered depending on the clinical circumstances, because these therapies are highly toxic and unlikely to offer lasting clinical benefit for patients with disseminated MCC. Due to lack of comparative trials, the literature is not directive regarding which cytotoxic therapies provide superior outcomes. However, there are data to support that MCC is chemosensitive, although the responses are not durable. For select cases, the multidisciplinary team may consider the following cytotoxic options for which at least some limited data show activity in MCC: cisplatin with or without etoposide, carboplatin with or without etoposide, topotecan, or the CAV combination therapy regimen (cyclophosphamide, doxorubicin [or epirubicin], and vincristine). There are no data regarding the optimal sequence of systemic therapies. Ongoing clinical trials are testing targeted therapies (eg, crizotinib) and other checkpoint immunotherapies in patients with MCC.

Follow-up and Recurrence

Patterns of Recurrence and Metastases

As described previously, several large studies (n > 100) document the development of recurrence in approximately 25% to 50% of all cases of MCC.^{5,15,18,25,26,30} Large meta-analyses have shown that at least half of patients with MCC develop lymph node metastases and nearly one third develop distant metastases.²³⁻²⁶ Smaller but more recent studies have reported similar or higher rates.²⁷⁻²⁹ Based on data from large retrospective analyses (n > 100), the median time to recurrence in patients with MCC is about 8 to 9 months, with 90% of the recurrences occurring within 24 months.^{5,30,52,179} Time to local recurrence is generally shorter than for regional recurrence, and time to distant metastasis is longer.^{15,18,30,239} Distant metastases have been shown to arise in a wide range of anatomic locations, as described in the previous section entitled *Detection of Distant Metastatic Disease*. Due to the fast-growing nature of the disease, detection of multiple distant metastases at once is not uncommon.¹⁶⁷



NCCN Guidelines Version 1.2022

Merkel Cell Carcinoma

Imaging Surveillance

Retrospective studies of follow-up imaging results have reported both local and systemic MCC recurrences detected by a variety of techniques, including (but not limited to) MRI,¹⁶⁷ CT,^{167,168,177} and FDG PET/CT.^{170,175-177,179,183,184,187} Data on the accuracy of different imaging techniques for follow-up surveillance are limited, because very few of these studies report whether or not the follow-up imaging findings were histologically confirmed.^{168,175,176} The yield from different imaging follow-up regimens and techniques is also unknown, as the available retrospective studies that evaluated imaging results did not clarify the frequency of follow-up surveillance or whether the patients were believed to have no evidence of disease prior to follow-up imaging. One retrospective study of 53 scans in 36 patients reported that FDG PET or FDG PET/CT results had a high impact on management plans in 45% of patients when used for “restaging or surveillance,” defined as scans taken more than 7 months after definitive treatment to assess suspected relapse or ongoing response.¹⁸⁴

Risk of Developing Secondary Cancers During Follow-up

As described in *Presence of Secondary Malignancy* above, patients who have had MCC are at increased risk for a second primary malignancy—either another primary MCC, a different skin cancer, or other types of noncutaneous malignancies.^{32,147,148,151,152} Large retrospective analyses have found that 9% to 19% of patients diagnosed with MCC subsequently develop another malignancy.^{3,147,148,151,152}

NCCN Recommendations for Follow-up

The NCCN Panel recommends close clinical follow-up for patients with MCC starting immediately after diagnosis and treatment. The physical examination should include a complete skin and complete lymph node examination every 3 to 6 months for the first 3 years, then every 6 to 12 months thereafter. The recommended frequency of follow-up visits is purposely broad to allow for an individualized schedule based on the risk

of recurrence, stage of disease, and other factors such as patient anxiety and clinician preference. The panel's recommendations for frequent clinical exams during the first 3 years also reflect the fact that MCC will recur in up to half of patients, and most recurrences occur within the first few years after diagnosis. Education regarding self-examination of the skin is useful for patients with MCC because of their increased risk for other non-melanoma skin cancers.

Imaging studies should be performed as clinically indicated, such as in cases of emergent adenopathy or organomegaly, unexplained changes in liver function tests, or development of new suspicious symptoms. For high-risk patients (eg, stage IIIB or higher, immunosuppression), routine imaging should be considered. Recommended imaging modality options are the same as for the initial clinical workup in patients for whom regional or distant metastases are suspected: brain MRI with contrast and neck/chest/abdomen/pelvis CT with contrast or whole-body FDG PET/CT. Whole-body FDG PET/CT scans may be useful to identify and quantify metastases, especially bone involvement. If whole-body FDG PET/CT is not available, CT or MRI with contrast may be used. As immunosuppressed patients are at high risk for recurrence, more frequent follow-up may be indicated. To lower the risk of recurrence/progression, immunosuppressive treatments should be minimized as clinically feasible.

As described in the section entitled *MCPyV*, MCPyV oncoprotein antibody testing performed at initial workup may help guide surveillance.⁵⁷⁻⁶⁰ Patients who are oncoprotein antibody seronegative at diagnosis may be at higher risk of recurrence and may benefit from more intensive surveillance.⁵⁷ For patients who are seropositive at baseline, the MCPyV oncoprotein antibody test may be a useful component of ongoing surveillance because a rising titer can be an early indicator of recurrence.⁵⁷



Treatment of Recurrence

Multiple retrospective analyses,^{66,126,128,248,253,266} analysis of data from a phase II study,²⁶⁰ and a few meta analyses^{24,246,255} have shown that recurrence of MCC is associated with poor prognosis. Collectively, results from these studies support that locoregional recurrence is associated with development of distant metastasis, and that all types of recurrences (local, regional, and distant) may be associated with poorer DSS and OS. A few retrospective studies did not find a significant association between recurrence and OS and/or DSS,^{143,224,249,252,253} and one retrospective study found that recurrence was not associated with any outcome measures (LRC, PFS, OS).⁵² Although patients with MCC recurrence (at baseline) were included in the patient population for many studies attempting to determine efficacy of specific treatments for MCC, few studies reported outcomes specifically for patients treated for recurrence.^{28,52,124,128,223,224,237,240,246,249,252-255,259,260,302} There are insufficient data from these studies to draw conclusions about the relative efficacy of treatments for recurrent disease. However, two studies provide some insight into factors associated with outcomes after treatment for recurrence, which may help inform decisions regarding aggressiveness of treatment. One retrospective analysis of 55 patients with recurrent MCC identified several factors associated with improved DSS after recurrence: location of primary MCC (at initial presentation), type of recurrence (local, regional, or distant), disease-free interval (between treatment of primary MCC and development of recurrence), and whether the patient was disease free after treatment for recurrence.²²³ Another retrospective analysis, including 70 patients with locoregional MCC recurrence, also found that the type of first recurrence and disease-free interval (between treatment of primary and first recurrence) were prognostic for development of subsequent distant recurrence, and that the disease-free interval was prognostic for OS.²⁵⁴

NCCN Recommendations for Treatment of Recurrence

Patients who present with local or regional recurrence should receive individualized treatment, as the treatment options depend on whether further surgery or radiation is possible. For disseminated recurrence, follow the treatment pathway for distant metastatic disease (clinical M1).



References

1. Paulson KG, Park SY, Vandeven NA, et al. Merkel cell carcinoma: Current US incidence and projected increases based on changing demographics. *J Am Acad Dermatol* 2018;78:457-463 e452. Available at: <https://www.ncbi.nlm.nih.gov/pubmed/29102486>.
2. Hodgson NC. Merkel cell carcinoma: changing incidence trends. *J Surg Oncol* 2005;89:1-4. Available at: <https://www.ncbi.nlm.nih.gov/pubmed/15611998>.
3. Reichgelt BA, Visser O. Epidemiology and survival of Merkel cell carcinoma in the Netherlands. A population-based study of 808 cases in 1993-2007. *Eur J Cancer* 2011;47:579-585. Available at: <http://www.ncbi.nlm.nih.gov/pubmed/21144740>.
4. Lyhne D, Lock-Andersen J, Dahlstrom K, et al. Rising incidence of Merkel cell carcinoma. *J Plast Surg Hand Surg* 2011;45:274-280. Available at: <https://www.ncbi.nlm.nih.gov/pubmed/22250719>.
5. Santamaria-Barria JA, Boland GM, Yeap BY, et al. Merkel cell carcinoma: 30-year experience from a single institution. *Ann Surg Oncol* 2013;20:1365-1373. Available at: <http://www.ncbi.nlm.nih.gov/pubmed/23208132>.
6. Youlden DR, Soyer HP, Youl PH, et al. Incidence and survival for Merkel cell carcinoma in Queensland, Australia, 1993-2010. *JAMA Dermatol* 2014;150:864-872. Available at: <https://www.ncbi.nlm.nih.gov/pubmed/24943712>.
7. Fitzgerald TL, Dennis S, Kachare SD, et al. Dramatic Increase in the Incidence and Mortality from Merkel Cell Carcinoma in the United States. *Am Surg* 2015;81:802-806. Available at: <http://www.ncbi.nlm.nih.gov/pubmed/26215243>.
8. Goon PK, Greenberg DC, Igali L, Levell NJ. Merkel Cell Carcinoma: rising incidence in the East of England. *J Eur Acad Dermatol Venereol* 2016;30:2052-2055. Available at: <https://www.ncbi.nlm.nih.gov/pubmed/27515234>.
9. Rubio-Casadevall J, Hernandez-Pujol AM, Ferreira-Santos MC, et al. Trends in incidence and survival analysis in non-melanoma skin cancer from 1994 to 2012 in Girona, Spain: A population-based study. *Cancer Epidemiol* 2016;45:6-10. Available at: <https://www.ncbi.nlm.nih.gov/pubmed/27639035>.
10. Zaar O, Gillstedt M, Lindelof B, et al. Merkel cell carcinoma incidence is increasing in Sweden. *J Eur Acad Dermatol Venereol* 2016. Available at: <http://www.ncbi.nlm.nih.gov/pubmed/27136306>.
11. Lemos B, Nghiem P. Merkel cell carcinoma: more deaths but still no pathway to blame. *J Invest Dermatol* 2007;127:2100-2103. Available at: <https://www.ncbi.nlm.nih.gov/pubmed/17700621>.
12. Eftekhari F, Wallace S, Silva EG, Lenzi R. Merkel cell carcinoma of the skin: imaging and clinical features in 93 cases. *Br J Radiol* 1996;69:226-233. Available at: <https://www.ncbi.nlm.nih.gov/pubmed/8800866>.
13. Walsh NM. Primary neuroendocrine (Merkel cell) carcinoma of the skin: morphologic diversity and implications thereof. *Hum Pathol* 2001;32:680-689. Available at: <https://www.ncbi.nlm.nih.gov/pubmed/11486166>.
14. Heath M, Jaimes N, Lemos B, et al. Clinical characteristics of Merkel cell carcinoma at diagnosis in 195 patients: the AEIOU features. *J Am Acad Dermatol* 2008;58:375-381. Available at: <https://www.ncbi.nlm.nih.gov/pubmed/18280333>.
15. Tarantola TI, Vallow LA, Halyard MY, et al. Prognostic factors in Merkel cell carcinoma: analysis of 240 cases. *J Am Acad Dermatol* 2013;68:425-432. Available at: <https://www.ncbi.nlm.nih.gov/pubmed/23200197>.
16. Suarez AL, Louis P, Kitts J, et al. Clinical and dermoscopic features of combined cutaneous squamous cell carcinoma (SCC)/neuroendocrine [Merkel cell] carcinoma (MCC). *J Am Acad Dermatol* 2015;73:968-975. Available at: <https://www.ncbi.nlm.nih.gov/pubmed/26433246>.



NCCN Guidelines Version 1.2022

Merkel Cell Carcinoma

17. Agelli M, Clegg LX. Epidemiology of primary Merkel cell carcinoma in the United States. *J Am Acad Dermatol* 2003;49:832-841. Available at: <http://www.ncbi.nlm.nih.gov/pubmed/14576661>.
18. Hitchcock CL, Bland KI, Laney RG, 3rd, et al. Neuroendocrine (Merkel cell) carcinoma of the skin. Its natural history, diagnosis, and treatment. *Ann Surg* 1988;207:201-207. Available at: <http://www.ncbi.nlm.nih.gov/pubmed/3277546>.
19. Lemos BD, Storer BE, Iyer JG, et al. Pathologic nodal evaluation improves prognostic accuracy in Merkel cell carcinoma: analysis of 5823 cases as the basis of the first consensus staging system. *J Am Acad Dermatol* 2010;63:751-761. Available at: <http://www.ncbi.nlm.nih.gov/pubmed/20646783>.
20. Albores-Saavedra J, Batich K, Chable-Montero F, et al. Merkel cell carcinoma demographics, morphology, and survival based on 3870 cases: a population based study. *J Cutan Pathol* 2010;37:20-27. Available at: <https://www.ncbi.nlm.nih.gov/pubmed/19638070>.
21. Harms KL, Healy MA, Nghiem P, et al. Analysis of prognostic factors from 9387 Merkel cell carcinoma cases forms the basis for the new 8th Edition AJCC Staging System. *Ann Surg Oncol* 2016;23:3564-3571. Available at: <https://www.ncbi.nlm.nih.gov/pubmed/27198511>.
22. Sridharan V, Muralidhar V, Margalit DN, et al. Merkel cell carcinoma: A population analysis on survival. *J Natl Compr Canc Netw* 2016;14:1247-1257. Available at: <https://www.ncbi.nlm.nih.gov/pubmed/27697979>.
23. Mercer D, Brander P, Liddell K. Merkel cell carcinoma: the clinical course. *Ann Plast Surg* 1990;25:136-141. Available at: <https://www.ncbi.nlm.nih.gov/pubmed/2204306>.
24. Pitale M, Sessions RB, Husain S. An analysis of prognostic factors in cutaneous neuroendocrine carcinoma. *Laryngoscope* 1992;102:244-249. Available at: <http://www.ncbi.nlm.nih.gov/pubmed/1545650>.
25. Akhtar S, Oza KK, Wright J. Merkel cell carcinoma: report of 10 cases and review of the literature. *J Am Acad Dermatol* 2000;43:755-767. Available at: <http://www.ncbi.nlm.nih.gov/pubmed/11050578>.
26. Medina-Franco H, Urist MM, Fiveash J, et al. Multimodality treatment of Merkel cell carcinoma: case series and literature review of 1024 cases. *Ann Surg Oncol* 2001;8:204-208. Available at: <http://www.ncbi.nlm.nih.gov/pubmed/11314935>.
27. McAfee WJ, Morris CG, Mendenhall CM, et al. Merkel cell carcinoma: treatment and outcomes. *Cancer* 2005;104:1761-1764. Available at: <http://www.ncbi.nlm.nih.gov/pubmed/16136596>.
28. Guler-Nizam E, Leiter U, Metzler G, et al. Clinical course and prognostic factors of Merkel cell carcinoma of the skin. *Br J Dermatol* 2009;161:90-94. Available at: <https://www.ncbi.nlm.nih.gov/pubmed/19438439>.
29. Lim CS, Whalley D, Haydu LE, et al. Increasing tumor thickness is associated with recurrence and poorer survival in patients with Merkel cell carcinoma. *Ann Surg Oncol* 2012;19:3325-3334. Available at: <https://www.ncbi.nlm.nih.gov/pubmed/22820936>.
30. Allen PJ, Bowne WB, Jaques DP, et al. Merkel cell carcinoma: prognosis and treatment of patients from a single institution. *J Clin Oncol* 2005;23:2300-2309. Available at: <http://www.ncbi.nlm.nih.gov/pubmed/15800320>.
31. Harrington C, Kwan W. Radiotherapy and conservative surgery in the locoregional management of Merkel cell carcinoma: The British Columbia Cancer Agency experience. *Ann Surg Oncol* 2016;23:573-578. Available at: <http://www.ncbi.nlm.nih.gov/pubmed/26286197>.
32. Kaae J, Hansen AV, Biggar RJ, et al. Merkel cell carcinoma: incidence, mortality, and risk of other cancers. *J Natl Cancer Inst* 2010;102:793-801. Available at: <https://www.ncbi.nlm.nih.gov/pubmed/20424236>.



NCCN Guidelines Version 1.2022

Merkel Cell Carcinoma

33. Asgari MM, Sokil MM, Warton EM, et al. Effect of host, tumor, diagnostic, and treatment variables on outcomes in a large cohort with Merkel cell carcinoma. *JAMA Dermatol* 2014;150:716-723. Available at: <https://www.ncbi.nlm.nih.gov/pubmed/24807619>.
34. Fields RC, Busam KJ, Chou JF, et al. Five hundred patients with merkel cell carcinoma evaluated at a single institution. *Ann Surg* 2011;254:465-475. Available at: <http://www.ncbi.nlm.nih.gov/pubmed/21865945>.
35. Miller RW, Rabkin CS. Merkel cell carcinoma and melanoma: etiological similarities and differences. *Cancer Epidemiol Biomarkers Prev* 1999;8:153-158. Available at: <https://www.ncbi.nlm.nih.gov/pubmed/10067813>.
36. Lanoy E, Costagliola D, Engels EA. Skin cancers associated with HIV infection and solid-organ transplantation among elderly adults. *Int J Cancer* 2010;126:1724-1731. Available at: <https://www.ncbi.nlm.nih.gov/pubmed/19810102>.
37. Lunder EJ, Stern RS. Merkel-cell carcinomas in patients treated with methoxsalen and ultraviolet A radiation. *N Engl J Med* 1998;339:1247-1248. Available at: <https://www.ncbi.nlm.nih.gov/pubmed/9786759>.
38. Smith FO, Yue B, Marzban SS, et al. Both tumor depth and diameter are predictive of sentinel lymph node status and survival in Merkel cell carcinoma. *Cancer* 2015;121:3252-3260. Available at: <http://www.ncbi.nlm.nih.gov/pubmed/26038193>.
39. Ezaldein HH, Ventura A, DeRuyter NP, et al. Understanding the influence of patient demographics on disease severity, treatment strategy, and survival outcomes in merkel cell carcinoma: a surveillance, epidemiology, and end-results study. *Oncoscience* 2017;4:106-114. Available at: <https://www.ncbi.nlm.nih.gov/pubmed/28966943>.
40. Heenan PJ, Cole JM, Spagnolo DV. Primary cutaneous neuroendocrine carcinoma (Merkel cell tumor). An adnexal epithelial neoplasm. *Am J Dermatopathol* 1990;12:7-16. Available at: <https://www.ncbi.nlm.nih.gov/pubmed/2138434>.
41. Higaki-Mori H, Kuwamoto S, Iwasaki T, et al. Association of Merkel cell polyomavirus infection with clinicopathological differences in Merkel cell carcinoma. *Hum Pathol* 2012;43:2282-2291. Available at: <https://www.ncbi.nlm.nih.gov/pubmed/22795182>.
42. Lai JH, Fleming KE, Ly TY, et al. Pure versus combined Merkel cell carcinomas: immunohistochemical evaluation of cellular proteins (p53, Bcl-2, and c-kit) reveals significant overexpression of p53 in combined tumors. *Hum Pathol* 2015;46:1290-1296. Available at: <https://www.ncbi.nlm.nih.gov/pubmed/26099430>.
43. Harms PW, Vats P, Verhaegen ME, et al. The distinctive mutational spectra of polyomavirus-negative Merkel cell carcinoma. *Cancer Res* 2015;75:3720-3727. Available at: <https://www.ncbi.nlm.nih.gov/pubmed/26238782>.
44. Wong SQ, Waldeck K, Vergara IA, et al. UV-associated mutations underlie the etiology of MCPyV-negative Merkel cell carcinomas. *Cancer Res* 2015;75:5228-5234. Available at: <https://www.ncbi.nlm.nih.gov/pubmed/26627015>.
45. Goh G, Walradt T, Markarov V, et al. Mutational landscape of MCPyV-positive and MCPyV-negative Merkel cell carcinomas with implications for immunotherapy. *Oncotarget* 2016;7:3403-3415. Available at: <https://www.ncbi.nlm.nih.gov/pubmed/26655088>.
46. Engels EA, Frisch M, Goedert JJ, et al. Merkel cell carcinoma and HIV infection. *Lancet* 2002;359:497-498. Available at: <https://www.ncbi.nlm.nih.gov/pubmed/11853800>.
47. Koljonen V, Kukko H, Tukiainen E, et al. Incidence of Merkel cell carcinoma in renal transplant recipients. *Nephrol Dial Transplant* 2009;24:3231-3235. Available at: <https://www.ncbi.nlm.nih.gov/pubmed/19586970>.
48. Koljonen V, Kukko H, Pukkala E, et al. Chronic lymphocytic leukaemia patients have a high risk of Merkel-cell polyomavirus DNA-positive Merkel-cell carcinoma. *Br J Cancer* 2009;101:1444-1447. Available at: <https://www.ncbi.nlm.nih.gov/pubmed/19755994>.



49. Koljonen V, Sahi H, Bohling T, Makisalo H. Post-transplant Merkel cell carcinoma. *Acta Derm Venereol* 2016;96:442-447. Available at: <https://www.ncbi.nlm.nih.gov/pubmed/26554531>.
50. Paulson KG, Iyer JG, Blom A, et al. Systemic immune suppression predicts diminished Merkel cell carcinoma-specific survival independent of stage. *J Invest Dermatol* 2013;133:642-646. Available at: <http://www.ncbi.nlm.nih.gov/pubmed/23190897>.
51. Liang E, Brower JV, Rice SR, et al. Merkel cell carcinoma analysis of outcomes: A 30-year experience. *PLoS One* 2015;10:e0129476. Available at: <https://www.ncbi.nlm.nih.gov/pubmed/26053480>.
52. Hui AC, Stillie AL, Seel M, Ainslie J. Merkel cell carcinoma: 27-year experience at the Peter MacCallum Cancer Centre. *Int J Radiat Oncol Biol Phys* 2011;80:1430-1435. Available at: <https://www.ncbi.nlm.nih.gov/pubmed/20708847>.
53. Feng H, Shuda M, Chang Y, Moore PS. Clonal integration of a polyomavirus in human Merkel cell carcinoma. *Science* 2008;319:1096-1100. Available at: <http://www.ncbi.nlm.nih.gov/pubmed/18202256>.
54. Rollison DE, Giuliano AR, Becker JC. New virus associated with merkel cell carcinoma development. *J Natl Compr Canc Netw* 2010;8:874-880. Available at: <http://www.ncbi.nlm.nih.gov/pubmed/20870633>.
55. Batinica M, Akgul B, Silling S, et al. Correlation of Merkel cell polyomavirus positivity with PDGFRalpha mutations and survivin expression in Merkel cell carcinoma. *J Dermatol Sci* 2015;79:43-49. Available at: <http://www.ncbi.nlm.nih.gov/pubmed/25936870>.
56. Santos-Juanes J, Fernandez-Vega I, Fuentes N, et al. Merkel cell carcinoma and Merkel cell polyomavirus: a systematic review and meta-analysis. *Br J Dermatol* 2015;173:42-49. Available at: <http://www.ncbi.nlm.nih.gov/pubmed/25919492>.
57. Paulson KG, Lewis CW, Redman MW, et al. Viral oncoprotein antibodies as a marker for recurrence of Merkel cell carcinoma: A prospective validation study. *Cancer* 2017;123:1464-1474. Available at: <https://www.ncbi.nlm.nih.gov/pubmed/27925665>.
58. Paulson KG, Carter JJ, Johnson LG, et al. Antibodies to merkel cell polyomavirus T antigen oncoproteins reflect tumor burden in merkel cell carcinoma patients. *Cancer Res* 2010;70:8388-8397. Available at: <http://www.ncbi.nlm.nih.gov/pubmed/20959478>.
59. Samimi M, Molet L, Fleury M, et al. Prognostic value of antibodies to Merkel cell polyomavirus T antigens and VP1 protein in patients with Merkel cell carcinoma. *Br J Dermatol* 2016;174:813-822. Available at: <http://www.ncbi.nlm.nih.gov/pubmed/26600395>.
60. Touze A, Le Bidre E, Laude H, et al. High levels of antibodies against merkel cell polyomavirus identify a subset of patients with merkel cell carcinoma with better clinical outcome. *J Clin Oncol* 2011;29:1612-1619. Available at: <http://www.ncbi.nlm.nih.gov/pubmed/21422439>.
61. Goepfert H, Remmler D, Silva E, Wheeler B. Merkel cell carcinoma (endocrine carcinoma of the skin) of the head and neck. *Arch Otolaryngol* 1984;110:707-712. Available at: <https://www.ncbi.nlm.nih.gov/pubmed/6487123>.
62. Ball NJ, Tanhuanco-Kho G. Merkel cell carcinoma frequently shows histologic features of basal cell carcinoma: a study of 30 cases. *J Cutan Pathol* 2007;34:612-619. Available at: <https://www.ncbi.nlm.nih.gov/pubmed/17640231>.
63. Frigerio B, Capella C, Eusebi V, et al. Merkel cell carcinoma of the skin: the structure and origin of normal Merkel cells. *Histopathology* 1983;7:229-249. Available at: <https://www.ncbi.nlm.nih.gov/pubmed/6852784>.
64. Gu J, Polak JM, Van Noorden S, et al. Immunostaining of neuron-specific enolase as a diagnostic tool for Merkel cell tumors. *Cancer* 1983;52:1039-1043. Available at: <https://www.ncbi.nlm.nih.gov/pubmed/6349776>.



65. Skelton HG, Smith KJ, Hitchcock CL, et al. Merkel cell carcinoma: analysis of clinical, histologic, and immunohistologic features of 132 cases with relation to survival. *J Am Acad Dermatol* 1997;37:734-739. Available at: <http://www.ncbi.nlm.nih.gov/pubmed/9366819>.

66. Llombart B, Monteagudo C, Lopez-Guerrero JA, et al. Clinicopathological and immunohistochemical analysis of 20 cases of Merkel cell carcinoma in search of prognostic markers. *Histopathology* 2005;46:622-634. Available at: <https://www.ncbi.nlm.nih.gov/pubmed/15910593>.

67. Anderson SE, Beer KT, Banic A, et al. MRI of merkel cell carcinoma: histologic correlation and review of the literature. *AJR Am J Roentgenol* 2005;185:1441-1448. Available at: <https://www.ncbi.nlm.nih.gov/pubmed/16303995>.

68. Gollard R, Weber R, Kosty MP, et al. Merkel cell carcinoma: review of 22 cases with surgical, pathologic, and therapeutic considerations. *Cancer* 2000;88:1842-1851. Available at: <https://www.ncbi.nlm.nih.gov/pubmed/10760761>.

69. Hall BJ, Pincus LB, Yu SS, et al. Immunohistochemical prognostication of Merkel cell carcinoma: p63 expression but not polyomavirus status correlates with outcome. *J Cutan Pathol* 2012;39:911-917. Available at: <https://www.ncbi.nlm.nih.gov/pubmed/22882157>.

70. Henderson SA, Tetzlaff MT, Pattanaprichakul P, et al. Detection of mitotic figures and G2+ tumor nuclei with histone markers correlates with worse overall survival in patients with Merkel cell carcinoma. *J Cutan Pathol* 2014;41:846-852. Available at: <https://www.ncbi.nlm.nih.gov/pubmed/25263506>.

71. Warner TF, Uno H, Hafez GR, et al. Merkel cells and Merkel cell tumors. Ultrastructure, immunocytochemistry and review of the literature. *Cancer* 1983;52:238-245. Available at: <https://www.ncbi.nlm.nih.gov/pubmed/6344978>.

72. Johansson L, Tennvall J, Akerman M. Immunohistochemical examination of 25 cases of Merkel cell carcinoma: a comparison with small cell carcinoma of the lung and oesophagus, and a review of the literature. *APMIS* 1990;98:741-752. Available at: <https://www.ncbi.nlm.nih.gov/pubmed/1698390>.

73. Haag ML, Glass LF, Fenske NA. Merkel cell carcinoma. Diagnosis and treatment. *Dermatol Surg* 1995;21:669-683. Available at: <http://www.ncbi.nlm.nih.gov/pubmed/7633811>.

74. Schmidt U, Muller U, Metz KA, Leder LD. Cytokeratin and neurofilament protein staining in Merkel cell carcinoma of the small cell type and small cell carcinoma of the lung. *Am J Dermatopathol* 1998;20:346-351. Available at: <https://www.ncbi.nlm.nih.gov/pubmed/9700371>.

75. Bobos M, Hytioglou P, Kostopoulos I, et al. Immunohistochemical distinction between merkel cell carcinoma and small cell carcinoma of the lung. *Am J Dermatopathol* 2006;28:99-104. Available at: <https://www.ncbi.nlm.nih.gov/pubmed/16625069>.

76. Kolhe R, Reid MD, Lee JR, et al. Immunohistochemical expression of PAX5 and TdT by Merkel cell carcinoma and pulmonary small cell carcinoma: a potential diagnostic pitfall but useful discriminatory marker. *Int J Clin Exp Pathol* 2013;6:142-147. Available at: <https://www.ncbi.nlm.nih.gov/pubmed/23329999>.

77. Moll R, Lowe A, Laufer J, Franke WW. Cytokeratin 20 in human carcinomas. A new histodiagnostic marker detected by monoclonal antibodies. *Am J Pathol* 1992;140:427-447. Available at: <https://www.ncbi.nlm.nih.gov/pubmed/1371204>.

78. Miettinen M. Keratin 20: immunohistochemical marker for gastrointestinal, urothelial, and Merkel cell carcinomas. *Mod Pathol* 1995;8:384-388. Available at: <https://www.ncbi.nlm.nih.gov/pubmed/7567935>.



NCCN Guidelines Version 1.2022

Merkel Cell Carcinoma

79. Chan JK, Suster S, Wenig BM, et al. Cytokeratin 20 immunoreactivity distinguishes Merkel cell (primary cutaneous neuroendocrine) carcinomas and salivary gland small cell carcinomas from small cell carcinomas of various sites. *Am J Surg Pathol* 1997;21:226-234. Available at: <https://www.ncbi.nlm.nih.gov/pubmed/9042291>.

80. Scott MP, Helm KF. Cytokeratin 20: a marker for diagnosing Merkel cell carcinoma. *Am J Dermatopathol* 1999;21:16-20. Available at: <http://www.ncbi.nlm.nih.gov/pubmed/10027519>.

81. Byrd-Gloster AL, Khoor A, Glass LF, et al. Differential expression of thyroid transcription factor 1 in small cell lung carcinoma and Merkel cell tumor. *Hum Pathol* 2000;31:58-62. Available at: <https://www.ncbi.nlm.nih.gov/pubmed/10665914>.

82. Hanly AJ, Elgart GW, Jorda M, et al. Analysis of thyroid transcription factor-1 and cytokeratin 20 separates merkel cell carcinoma from small cell carcinoma of lung. *J Cutan Pathol* 2000;27:118-120. Available at: <http://www.ncbi.nlm.nih.gov/pubmed/10728812>.

83. Ordonez NG. Value of thyroid transcription factor-1 immunostaining in distinguishing small cell lung carcinomas from other small cell carcinomas. *Am J Surg Pathol* 2000;24:1217-1223. Available at: <https://www.ncbi.nlm.nih.gov/pubmed/10976695>.

84. Cheuk W, Kwan MY, Suster S, Chan JK. Immunostaining for thyroid transcription factor 1 and cytokeratin 20 aids the distinction of small cell carcinoma from Merkel cell carcinoma, but not pulmonary from extrapulmonary small cell carcinomas. *Arch Pathol Lab Med* 2001;125:228-231. Available at: <http://www.ncbi.nlm.nih.gov/pubmed/11175640>.

85. Leech SN, Kolar AJ, Barrett PD, et al. Merkel cell carcinoma can be distinguished from metastatic small cell carcinoma using antibodies to cytokeratin 20 and thyroid transcription factor 1. *J Clin Pathol* 2001;54:727-729. Available at: <https://www.ncbi.nlm.nih.gov/pubmed/11533085>.

86. Busam KJ, Jungbluth AA, Rekthman N, et al. Merkel cell polyomavirus expression in merkel cell carcinomas and its absence in combined tumors and pulmonary neuroendocrine carcinomas. *Am J Surg Pathol* 2009;33:1378-1385. Available at: <https://www.ncbi.nlm.nih.gov/pubmed/19609205>.

87. Jensen K, Kohler S, Rouse RV. Cytokeratin staining in Merkel cell carcinoma: an immunohistochemical study of cytokeratins 5/6, 7, 17, and 20. *Appl Immunohistochem Mol Morphol* 2000;8:310-315. Available at: <https://www.ncbi.nlm.nih.gov/pubmed/11127923>.

88. Asioli S, Righi A, de Biase D, et al. Expression of p63 is the sole independent marker of aggressiveness in localised (stage I-II) Merkel cell carcinomas. *Mod Pathol* 2011;24:1451-1461. Available at: <https://www.ncbi.nlm.nih.gov/pubmed/21765392>.

89. Kim J, McNiff JM. Nuclear expression of survivin portends a poor prognosis in Merkel cell carcinoma. *Mod Pathol* 2008;21:764-769. Available at: <https://www.ncbi.nlm.nih.gov/pubmed/18425079>.

90. Acebo E, Vidaurrezaga N, Varas C, et al. Merkel cell carcinoma: a clinicopathological study of 11 cases. *J Eur Acad Dermatol Venereol* 2005;19:546-551. Available at: <https://www.ncbi.nlm.nih.gov/pubmed/16164706>.

91. Sidiropoulos M, Hanna W, Raphael SJ, Ghorab Z. Expression of TdT in Merkel cell carcinoma and small cell lung carcinoma. *Am J Clin Pathol* 2011;135:831-838. Available at: <https://www.ncbi.nlm.nih.gov/pubmed/21571955>.

92. Marghalani S, Feller JK, Mahalingam M, Mirzabeigi M. Huntingtin interacting protein 1 as a histopathologic adjunct in the diagnosis of Merkel cell carcinoma. *Int J Dermatol* 2015;54:640-647. Available at: <https://www.ncbi.nlm.nih.gov/pubmed/25070010>.

93. Sibley RK, Dahl D. Primary neuroendocrine (Merkel cell?) carcinoma of the skin. II. An immunocytochemical study of 21 cases. *Am J Surg Pathol* 1985;9:109-116. Available at: <https://www.ncbi.nlm.nih.gov/pubmed/2579592>.



NCCN Guidelines Version 1.2022

Merkel Cell Carcinoma

94. Visscher D, Cooper PH, Zarbo RJ, Crissman JD. Cutaneous neuroendocrine (Merkel cell) carcinoma: an immunophenotypic, clinicopathologic, and flow cytometric study. *Mod Pathol* 1989;2:331-338. Available at: <https://www.ncbi.nlm.nih.gov/pubmed/2668940>.

95. Shah IA, Netto D, Schlageter MO, et al. Neurofilament immunoreactivity in Merkel-cell tumors: a differentiating feature from small-cell carcinoma. *Mod Pathol* 1993;6:3-9. Available at: <https://www.ncbi.nlm.nih.gov/pubmed/7678934>.

96. Koljonen V, Haglund C, Tukiainen E, Bohling T. Neuroendocrine differentiation in primary Merkel cell carcinoma--possible prognostic significance. *Anticancer Res* 2005;25:853-858. Available at: <https://www.ncbi.nlm.nih.gov/pubmed/15868919>.

97. Knopf A, Bas M, Hofauer B, et al. Clinicopathological characteristics of head and neck Merkel cell carcinomas. *Head Neck* 2017;39:92-97. Available at: <https://www.ncbi.nlm.nih.gov/pubmed/27447124>.

98. Leong AS, Phillips GE, Pieterse AS, Milios J. Criteria for the diagnosis of primary endocrine carcinoma of the skin (Merkel cell carcinoma). A histological, immunohistochemical and ultrastructural study of 13 cases. *Pathology* 1986;18:393-399. Available at: <https://www.ncbi.nlm.nih.gov/pubmed/2434904>.

99. Gould VE, Wiedenmann B, Lee I, et al. Synaptophysin expression in neuroendocrine neoplasms as determined by immunocytochemistry. *Am J Pathol* 1987;126:243-257. Available at: <https://www.ncbi.nlm.nih.gov/pubmed/3103452>.

100. Panse G, McNiff JM, Ko CJ. Basal cell carcinoma: CD56 and cytokeratin 5/6 staining patterns in the differential diagnosis with Merkel cell carcinoma. *J Cutan Pathol* 2017;44:553-556. Available at: <https://www.ncbi.nlm.nih.gov/pubmed/28403527>.

101. Smith KJ, Skelton HG, 3rd, Holland TT, et al. Neuroendocrine (Merkel cell) carcinoma with an intraepidermal component. *Am J Dermatopathol* 1993;15:528-533. Available at: <https://www.ncbi.nlm.nih.gov/pubmed/8311181>.

102. Saeb-Lima M, Montante-Montes de Oca D, Albores-Saavedra J. Merkel cell carcinoma with eccrine differentiation: a clinicopathologic study of 7 cases. *Ann Diagn Pathol* 2008;12:410-414. Available at: <https://www.ncbi.nlm.nih.gov/pubmed/18995205>.

103. Martin B, Poblet E, Rios JJ, et al. Merkel cell carcinoma with divergent differentiation: histopathological and immunohistochemical study of 15 cases with PCR analysis for Merkel cell polyomavirus. *Histopathology* 2013;62:711-722. Available at: <https://www.ncbi.nlm.nih.gov/pubmed/23530585>.

104. D'Agostino M, Cinelli C, Willard R, et al. Epidermotropic Merkel cell carcinoma: a case series with histopathologic examination. *J Am Acad Dermatol* 2010;62:463-468. Available at: <https://www.ncbi.nlm.nih.gov/pubmed/20159312>.

105. Miner AG, Patel RM, Wilson DA, et al. Cytokeratin 20-negative Merkel cell carcinoma is infrequently associated with the Merkel cell polyomavirus. *Mod Pathol* 2015;28:498-504. Available at: <https://www.ncbi.nlm.nih.gov/pubmed/25394777>.

106. Pulitzer MP, Brannon AR, Berger MF, et al. Cutaneous squamous and neuroendocrine carcinoma: genetically and immunohistochemically different from Merkel cell carcinoma. *Mod Pathol* 2015;28:1023-1032. Available at: <https://www.ncbi.nlm.nih.gov/pubmed/26022453>.

107. Mott RT, Smoller BR, Morgan MB. Merkel cell carcinoma: a clinicopathologic study with prognostic implications. *J Cutan Pathol* 2004;31:217-223. Available at: <https://www.ncbi.nlm.nih.gov/pubmed/14984573>.

108. Kukko HM, Koljonen VS, Tukiainen EJ, et al. Vascular invasion is an early event in pathogenesis of Merkel cell carcinoma. *Mod Pathol* 2010;23:1151-1156. Available at: <https://www.ncbi.nlm.nih.gov/pubmed/20473275>.



109. Sihto H, Kukko H, Koljonen V, et al. Merkel cell polyomavirus infection, large T antigen, retinoblastoma protein and outcome in Merkel cell carcinoma. Clin Cancer Res 2011;17:4806-4813. Available at: <https://www.ncbi.nlm.nih.gov/pubmed/21642382>.

110. Zaragoza J, Kervarrec T, Touze A, et al. A high neutrophil-to-lymphocyte ratio as a potential marker of mortality in patients with Merkel cell carcinoma: A retrospective study. J Am Acad Dermatol 2016;75:712-721 e711. Available at: <https://www.ncbi.nlm.nih.gov/pubmed/27544490>.

111. Schrama D, Peitsch WK, Zapatka M, et al. Merkel cell polyomavirus status is not associated with clinical course of Merkel cell carcinoma. J Invest Dermatol 2011;131:1631-1638. Available at: <https://www.ncbi.nlm.nih.gov/pubmed/21562568>.

112. Amin MB, Edge S, Greene F, et al., eds. AJCC Cancer Staging Manual (ed 8th). New York: Springer International Publishing; 2017.

113. Rao P, Balzer BL, Lemos BD, et al. Protocol for the examination of specimens from patients with merkel cell carcinoma of the skin. Arch Pathol Lab Med 2010;134:341-344. Available at: <http://www.ncbi.nlm.nih.gov/pubmed/20196661>.

114. Smoller BR, Bichakjian CK, Brown JA, et al. Protocol for the Examination of Specimens From Patients With Merkel Cell Carcinoma of the Skin, Version 4.0.0.1. College of American Pathologists Cancer Protocol Templates 2017. Available at: <http://www.cap.org/ShowProperty?nodePath=/UCMCon/Contribution%20Folders/WebContent/pdf/cp-skin-merkelcell-17protocol-4001.pdf>.

115. Bhatia S, Storer BE, Iyer JG, et al. Adjuvant radiation therapy and chemotherapy in Merkel cell carcinoma: survival analyses of 6908 cases from the National Cancer Data Base. J Natl Cancer Inst 2016;108. Available at: <http://www.ncbi.nlm.nih.gov/pubmed/27245173>.

116. Smith VA, Camp ER, Lentsch EJ. Merkel cell carcinoma: identification of prognostic factors unique to tumors located in the head and neck based on analysis of SEER data. Laryngoscope 2012;122:1283-1290. Available at: <https://www.ncbi.nlm.nih.gov/pubmed/22522673>.

117. Marcoval J, Ferreres JR, Penin RM, et al. Merkel cell carcinoma: differences between sun-exposed and non-sun-exposed variants--a clinical analysis of 36 cases. Dermatology 2014;229:205-209. Available at: <https://www.ncbi.nlm.nih.gov/pubmed/25278300>.

118. Iyer JG, Storer BE, Paulson KG, et al. Relationships among primary tumor size, number of involved nodes, and survival for 8044 cases of Merkel cell carcinoma. J Am Acad Dermatol 2014;70:637-643. Available at: <https://www.ncbi.nlm.nih.gov/pubmed/24521828>.

119. Fields RC, Busam KJ, Chou JF, et al. Recurrence and survival in patients undergoing sentinel lymph node biopsy for merkel cell carcinoma: analysis of 153 patients from a single institution. Ann Surg Oncol 2011;18:2529-2537. Available at: <https://www.ncbi.nlm.nih.gov/pubmed/21431988>.

120. Schwartz JL, Griffith KA, Lowe L, et al. Features predicting sentinel lymph node positivity in Merkel cell carcinoma. J Clin Oncol 2011;29:1036-1041. Available at: <http://www.ncbi.nlm.nih.gov/pubmed/21300936>.

121. Andea AA, Coit DG, Amin B, Busam KJ. Merkel cell carcinoma: histologic features and prognosis. Cancer 2008;113:2549-2558. Available at: <http://www.ncbi.nlm.nih.gov/pubmed/18798233>.

122. Jabbour J, Cumming R, Scolyer RA, et al. Merkel cell carcinoma: assessing the effect of wide local excision, lymph node dissection, and radiotherapy on recurrence and survival in early-stage disease--results from a review of 82 consecutive cases diagnosed between 1992 and 2004. Ann Surg Oncol 2007;14:1943-1952. Available at: <http://www.ncbi.nlm.nih.gov/pubmed/17356954>.

123. Ott MJ, Tanabe KK, Gadd MA, et al. Multimodality management of Merkel cell carcinoma. Arch Surg 1999;134:388-392; discussion 392-383. Available at: <http://www.ncbi.nlm.nih.gov/pubmed/10199311>.



124. Gillenwater AM, Hessel AC, Morrison WH, et al. Merkel cell carcinoma of the head and neck: effect of surgical excision and radiation on recurrence and survival. Arch Otolaryngol Head Neck Surg 2001;127:149-154. Available at: <http://www.ncbi.nlm.nih.gov/pubmed/11177031>.

125. Sandel HDt, Day T, Richardson MS, et al. Merkel cell carcinoma: does tumor size or depth of invasion correlate with recurrence, metastasis, or patient survival? Laryngoscope 2006;116:791-795. Available at: <https://www.ncbi.nlm.nih.gov/pubmed/16652089>.

126. Poulsen M, Round C, Keller J, et al. Factors influencing relapse-free survival in Merkel cell carcinoma of the lower limb--a review of 60 cases. Int J Radiat Oncol Biol Phys 2010;76:393-397. Available at: <https://www.ncbi.nlm.nih.gov/pubmed/19515508>.

127. Fields RC, Busam KJ, Chou JF, et al. Recurrence after complete resection and selective use of adjuvant therapy for stage I through III Merkel cell carcinoma. Cancer 2012;118:3311-3320. Available at: <http://www.ncbi.nlm.nih.gov/pubmed/22072529>.

128. Balakrishnan V, Berry S, Stew B, Sizeland A. Benefits of combined modality treatment of Merkel cell carcinoma of the head and neck: single institution experience. J Laryngol Otol 2013;127:908-916. Available at: <https://www.ncbi.nlm.nih.gov/pubmed/23952972>.

129. Asiola S, Righi A, Volante M, et al. p63 expression as a new prognostic marker in Merkel cell carcinoma. Cancer 2007;110:640-647. Available at: <https://www.ncbi.nlm.nih.gov/pubmed/17599745>.

130. Goldberg SR, Neifeld JP, Frable WJ. Prognostic value of tumor thickness in patients with Merkel cell carcinoma. J Surg Oncol 2007;95:618-622. Available at: <https://www.ncbi.nlm.nih.gov/pubmed/17345617>.

131. Izikson L, Helm T, Sroa N, Zeitouni NC. Clinical stage of Merkel cell carcinoma and survival are not associated with Breslow thickness of biopsied tumor. Dermatol Surg 2012;38:1351-1356. Available at: <https://www.ncbi.nlm.nih.gov/pubmed/22455371>.

132. Feldmeyer L, Hudgens CW, Ray-Lyons G, et al. Density, distribution, and composition of immune infiltrates correlate with survival in Merkel cell carcinoma. Clin Cancer Res 2016;22:5553-5563. Available at: <https://www.ncbi.nlm.nih.gov/pubmed/27166398>.

133. Fleming KE, Ly TY, Pasternak S, et al. Support for p63 expression as an adverse prognostic marker in Merkel cell carcinoma: report on a Canadian cohort. Hum Pathol 2014;45:952-960. Available at: <https://www.ncbi.nlm.nih.gov/pubmed/24746200>.

134. Iwasaki T, Matsushita M, Nonaka D, et al. Phosphohistone-H3 (PHH3) is prognostic relevant in Merkel cell carcinomas but Merkel cell polyomavirus is a more powerful prognostic factor than AJCC clinical stage, PHH3, Ki-67 or mitotic indices. Pathol Int 2015;65:404-409. Available at: <https://www.ncbi.nlm.nih.gov/pubmed/25982855>.

135. Husein-ElAhmed H, Ramos-Pleguezuelos F, Ruiz-Molina I, et al. Histological features, p53, c-Kit, and poliomyavirus status and impact on survival in Merkel cell carcinoma patients. Am J Dermatopathol 2016;38:571-579. Available at: <https://www.ncbi.nlm.nih.gov/pubmed/27442046>.

136. Pilotti S, Rilke F, Bartoli C, Grisotti A. Clinicopathologic correlations of cutaneous neuroendocrine Merkel cell carcinoma. J Clin Oncol 1988;6:1863-1873. Available at: <https://www.ncbi.nlm.nih.gov/pubmed/3199169>.

137. Schwartz JL, Bichakjian CK, Lowe L, et al. Clinicopathologic features of primary Merkel cell carcinoma: a detailed descriptive analysis of a large contemporary cohort. Dermatol Surg 2013;39:1009-1016. Available at: <http://www.ncbi.nlm.nih.gov/pubmed/23551620>.

138. Beer TW, Ng LB, Murray K. Mast cells have prognostic value in Merkel cell carcinoma. Am J Dermatopathol 2008;30:27-30. Available at: <https://www.ncbi.nlm.nih.gov/pubmed/18212540>.



139. Johnson ME, Zhu F, Li T, et al. Absolute lymphocyte count: a potential prognostic factor for Merkel cell carcinoma. *J Am Acad Dermatol* 2014;70:1028-1035. Available at: <https://www.ncbi.nlm.nih.gov/pubmed/24666998>.

140. Paulson KG, Iyer JG, Tegeder AR, et al. Transcriptome-wide studies of merkel cell carcinoma and validation of intratumoral CD8+ lymphocyte invasion as an independent predictor of survival. *J Clin Oncol* 2011;29:1539-1546. Available at: <http://www.ncbi.nlm.nih.gov/pubmed/21422430>.

141. Paulson KG, Iyer JG, Simonson WT, et al. CD8+ lymphocyte intratumoral infiltration as a stage-independent predictor of Merkel cell carcinoma survival: a population-based study. *Am J Clin Pathol* 2014;142:452-458. Available at: <https://www.ncbi.nlm.nih.gov/pubmed/25239411>.

142. Kervarrec T, Gaboriaud P, Berthon P, et al. Merkel cell carcinomas infiltrated with CD33(+) myeloid cells and CD8(+) T cells are associated with improved outcome. *J Am Acad Dermatol* 2018;78:973-982 e978. Available at: <https://www.ncbi.nlm.nih.gov/pubmed/29273486>.

143. Boyle F, Pendlebury S, Bell D. Further insights into the natural history and management of primary cutaneous neuroendocrine (Merkel cell) carcinoma. *Int J Radiat Oncol Biol Phys* 1995;31:315-323. Available at: <https://www.ncbi.nlm.nih.gov/pubmed/7836085>.

144. Brenner B, Sulkes A, Rakowsky E, et al. Second neoplasms in patients with Merkel cell carcinoma. *Cancer* 2001;91:1358-1362. Available at: <https://www.ncbi.nlm.nih.gov/pubmed/11283937>.

145. Eich HT, Eich D, Staar S, et al. Role of postoperative radiotherapy in the management of Merkel cell carcinoma. *Am J Clin Oncol* 2002;25:50-56. Available at: <https://www.ncbi.nlm.nih.gov/pubmed/11823697>.

146. Eng TY, Boersma MG, Fuller CD, et al. Treatment of merkel cell carcinoma. *Am J Clin Oncol* 2004;27:510-515. Available at: <https://www.ncbi.nlm.nih.gov/pubmed/15596922>.

147. Koljonen V, Kukko H, Tukiainen E, et al. Second cancers following the diagnosis of Merkel cell carcinoma: a nationwide cohort study. *Cancer Epidemiol* 2010;34:62-65. Available at: <https://www.ncbi.nlm.nih.gov/pubmed/20061203>.

148. Bzhalava D, Bray F, Storm H, Dillner J. Risk of second cancers after the diagnosis of Merkel cell carcinoma in Scandinavia. *Br J Cancer* 2011;104:178-180. Available at: <https://www.ncbi.nlm.nih.gov/pubmed/21081931>.

149. Penn I, First MR. Merkel's cell carcinoma in organ recipients: report of 41 cases. *Transplantation* 1999;68:1717-1721. Available at: <https://www.ncbi.nlm.nih.gov/pubmed/10609948>.

150. Buell JF, Trofe J, Hanaway MJ, et al. Immunosuppression and Merkel cell cancer. *Transplant Proc* 2002;34:1780-1781. Available at: <https://www.ncbi.nlm.nih.gov/pubmed/12176573>.

151. Howard RA, Dores GM, Curtis RE, et al. Merkel cell carcinoma and multiple primary cancers. *Cancer Epidemiol Biomarkers Prev* 2006;15:1545-1549. Available at: <https://www.ncbi.nlm.nih.gov/pubmed/16896047>.

152. Youlden DR, Youl PH, Peter Soyer H, et al. Multiple primary cancers associated with Merkel cell carcinoma in Queensland, Australia, 1982-2011. *J Invest Dermatol* 2014;134:2883-2889. Available at: <https://www.ncbi.nlm.nih.gov/pubmed/24991966>.

153. Koljonen V, Rantanen M, Sahi H, et al. Joint occurrence of Merkel cell carcinoma and non-Hodgkin lymphomas in four Nordic countries. *Leuk Lymphoma* 2015;56:3315-3319. Available at: <https://www.ncbi.nlm.nih.gov/pubmed/25899400>.

154. Gomez LG, DiMaio S, Silva EG, Mackay B. Association between neuroendocrine (Merkel cell) carcinoma and squamous carcinoma of the skin. *Am J Surg Pathol* 1983;7:171-177. Available at: <https://www.ncbi.nlm.nih.gov/pubmed/6859392>.



155. Boutilier R, Desormeau L, Cragg F, et al. Merkel cell carcinoma: squamous and atypical fibroxanthoma-like differentiation in successive local tumor recurrences. *Am J Dermatopathol* 2001;23:46-49. Available at: <https://www.ncbi.nlm.nih.gov/pubmed/11176052>.
156. Aydin A, Kocer NE, Bekerecioglu M, Sari I. Cutaneous undifferentiated small (Merkel) cell carcinoma, that developed synchronously with multiple actinic keratoses, squamous cell carcinomas and basal cell carcinoma. *J Dermatol* 2003;30:241-244. Available at: <https://www.ncbi.nlm.nih.gov/pubmed/12692363>.
157. Ferringer T, Rogers HC, Metcalf JS. Merkel cell carcinoma in situ. *J Cutan Pathol* 2005;32:162-165. Available at: <https://www.ncbi.nlm.nih.gov/pubmed/15606676>.
158. Vieites B, Suarez-Penaranda JM, Delgado V, et al. Merkel cell carcinoma associated with in situ and invasive squamous cell carcinoma. *Acta Derm Venereol* 2009;89:184-186. Available at: <https://www.ncbi.nlm.nih.gov/pubmed/19326009>.
159. Tanahashi J, Kashima K, Daa T, et al. Merkel cell carcinoma co-existent with sebaceous carcinoma of the eyelid. *J Cutan Pathol* 2009;36:983-986. Available at: <https://www.ncbi.nlm.nih.gov/pubmed/19017040>.
160. Cirillo F. Neuroendocrine tumors and their association with rare tumors: observation of 4 cases. *Eur Rev Med Pharmacol Sci* 2010;14:577-588. Available at: <https://www.ncbi.nlm.nih.gov/pubmed/20707247>.
161. Koba S, Inoue T, Okawa T, et al. Merkel cell carcinoma with cytokeratin 20-negative and thyroid transcription factor-1-positive immunostaining admixed with squamous cell carcinoma. *J Dermatol Sci* 2011;64:77-79. Available at: <https://www.ncbi.nlm.nih.gov/pubmed/21775107>.
162. Mitteldorf C, Mertz KD, Fernandez-Figueras MT, et al. Detection of Merkel cell polyomavirus and human papillomaviruses in Merkel cell carcinoma combined with squamous cell carcinoma in immunocompetent European patients. *Am J Dermatopathol* 2012;34:506-510. Available at: <https://www.ncbi.nlm.nih.gov/pubmed/22505039>.
163. Ly TY, Walsh NM, Pasternak S. The spectrum of Merkel cell polyomavirus expression in Merkel cell carcinoma, in a variety of cutaneous neoplasms, and in neuroendocrine carcinomas from different anatomical sites. *Hum Pathol* 2012;43:557-566. Available at: <https://www.ncbi.nlm.nih.gov/pubmed/21940035>.
164. Ishida M, Okabe H. Merkel cell carcinoma concurrent with Bowen's disease: two cases, one with an unusual immunophenotype. *J Cutan Pathol* 2013;40:839-843. Available at: <https://www.ncbi.nlm.nih.gov/pubmed/23672777>.
165. Iwasaki T, Matsushita M, Kuwamoto S, et al. Usefulness of significant morphologic characteristics in distinguishing between Merkel cell polyomavirus-positive and Merkel cell polyomavirus-negative Merkel cell carcinomas. *Hum Pathol* 2013;44:1912-1917. Available at: <https://www.ncbi.nlm.nih.gov/pubmed/23664542>.
166. Kuwamoto S, Higaki H, Kanai K, et al. Association of Merkel cell polyomavirus infection with morphologic differences in Merkel cell carcinoma. *Hum Pathol* 2011;42:632-640. Available at: <http://www.ncbi.nlm.nih.gov/pubmed/21277612>.
167. Kouzmina M, Koljonen V, Leikola J, et al. Frequency and locations of systemic metastases in Merkel cell carcinoma by imaging. *Acta Radiol Open* 2017;6:2058460117700449. Available at: <https://www.ncbi.nlm.nih.gov/pubmed/28540062>.
168. Gollub MJ, Gruen DR, Dershaw DD. Merkel cell carcinoma: CT findings in 12 patients. *AJR Am J Roentgenol* 1996;167:617-620. Available at: <https://www.ncbi.nlm.nih.gov/pubmed/8751663>.



NCCN Guidelines Version 1.2022

Merkel Cell Carcinoma

169. Gupta SG, Wang LC, Penas PF, et al. Sentinel lymph node biopsy for evaluation and treatment of patients with Merkel cell carcinoma: The Dana-Farber experience and meta-analysis of the literature. Arch Dermatol 2006;142:685-690. Available at: <http://www.ncbi.nlm.nih.gov/pubmed/16785370>.

170. Peloschek P, Novotny C, Mueller-Mang C, et al. Diagnostic imaging in Merkel cell carcinoma: lessons to learn from 16 cases with correlation of sonography, CT, MRI and PET. Eur J Radiol 2010;73:317-323. Available at: <https://www.ncbi.nlm.nih.gov/pubmed/19108971>.

171. Colgan MB, Tarantola TI, Weaver AL, et al. The predictive value of imaging studies in evaluating regional lymph node involvement in Merkel cell carcinoma. J Am Acad Dermatol 2012;67:1250-1256. Available at: <https://www.ncbi.nlm.nih.gov/pubmed/22552001>.

172. Kwekkeboom DJ, Hoff AM, Lamberts SW, et al. Somatostatin analogue scintigraphy. A simple and sensitive method for the in vivo visualization of Merkel cell tumors and their metastases. Arch Dermatol 1992;128:818-821. Available at: <https://www.ncbi.nlm.nih.gov/pubmed/1599271>.

173. Guitera-Rovel P, Lumbroso J, Gautier-Gougis MS, et al. Indium-111 octreotide scintigraphy of Merkel cell carcinomas and their metastases. Ann Oncol 2001;12:807-811. Available at: <https://www.ncbi.nlm.nih.gov/pubmed/11484956>.

174. Durani BK, Klein A, Henze M, et al. Somatostatin analogue scintigraphy in Merkel cell tumours. Br J Dermatol 2003;148:1135-1140. Available at: <https://www.ncbi.nlm.nih.gov/pubmed/12828740>.

175. Belhocine T, Pierard GE, Fruhling J, et al. Clinical added-value of 18FDG PET in neuroendocrine-merkel cell carcinoma. Oncol Rep 2006;16:347-352. Available at: <https://www.ncbi.nlm.nih.gov/pubmed/16820914>.

176. Concannon R, Larcos GS, Veness M. The impact of (18)F-FDG PET-CT scanning for staging and management of Merkel cell carcinoma: results from Westmead Hospital, Sydney, Australia. J Am Acad Dermatol 2010;62:76-84. Available at: <http://www.ncbi.nlm.nih.gov/pubmed/20082888>.

177. Maury G, Dereure O, Du-Thanh A, et al. Interest of (18)F-FDG PET-CT scanning for staging and management of merkel cell carcinoma: a retrospective study of 15 patients. J Eur Acad Dermatol Venereol 2011;25:1420-1427. Available at: <https://www.ncbi.nlm.nih.gov/pubmed/21366705>.

178. Siva S, Byrne K, Seel M, et al. 18F-FDG PET provides high-impact and powerful prognostic stratification in the staging of Merkel cell carcinoma: a 15-year institutional experience. J Nucl Med 2013;54:1223-1229. Available at: <https://www.ncbi.nlm.nih.gov/pubmed/23753187>.

179. Hawryluk EB, O'Regan KN, Sheehy N, et al. Positron emission tomography/computed tomography imaging in Merkel cell carcinoma: a study of 270 scans in 97 patients at the Dana-Farber/Brigham and Women's Cancer Center. J Am Acad Dermatol 2013;68:592-599. Available at: <http://www.ncbi.nlm.nih.gov/pubmed/23127473>.

180. Ibrahim SF, Ahronowitz I, McCalmont TH, et al. 18F-fluorodeoxyglucose positron emission tomography-computed tomography imaging in the management of Merkel cell carcinoma: a single-institution retrospective study. Dermatol Surg 2013;39:1323-1333. Available at: <https://www.ncbi.nlm.nih.gov/pubmed/23777452>.

181. Treglia G, Kakhki VR, Giovanella L, Sadeghi R. Diagnostic performance of fluorine-18-fluorodeoxyglucose positron emission tomography in patients with Merkel cell carcinoma: a systematic review and meta-analysis. Am J Clin Dermatol 2013;14:437-447. Available at: <https://www.ncbi.nlm.nih.gov/pubmed/23959776>.

182. Buder K, Lapa C, Kreissl MC, et al. Somatostatin receptor expression in Merkel cell carcinoma as target for molecular imaging. BMC Cancer 2014;14:268. Available at: <https://www.ncbi.nlm.nih.gov/pubmed/24742330>.



NCCN Guidelines Version 1.2022

Merkel Cell Carcinoma

183. George A, Girault S, Testard A, et al. The impact of (18)F-FDG-PET/CT on Merkel cell carcinoma management: a retrospective study of 66 scans from a single institution. Nucl Med Commun 2014;35:282-290. Available at: <https://www.ncbi.nlm.nih.gov/pubmed/24240193>.

184. Byrne K, Siva S, Chait L, et al. 15-year experience of 18F-FDG PET imaging in response assessment and restaging after definitive treatment of Merkel cell carcinoma. J Nucl Med 2015;56:1328-1333. Available at: <http://www.ncbi.nlm.nih.gov/pubmed/26159592>.

185. Liu J, Larcos G, Howle J, Veness M. Lack of clinical impact of (18) F-fluorodeoxyglucose positron emission tomography with simultaneous computed tomography for stage I and II Merkel cell carcinoma with concurrent sentinel lymph node biopsy staging: A single institutional experience from Westmead Hospital, Sydney. Australas J Dermatol 2017;58:99-105. Available at: <https://www.ncbi.nlm.nih.gov/pubmed/26459330>.

186. Sollini M, Taralli S, Milella M, et al. Somatostatin receptor positron emission tomography/computed tomography imaging in Merkel cell carcinoma. J Eur Acad Dermatol Venereol 2016;30:1507-1511. Available at: <https://www.ncbi.nlm.nih.gov/pubmed/26446694>.

187. Ben-Haim S, Garkaby J, Primashvili N, et al. Metabolic assessment of Merkel cell carcinoma: the role of 18F-FDG PET/CT. Nucl Med Commun 2016;37:865-873. Available at: <https://www.ncbi.nlm.nih.gov/pubmed/27092665>.

188. Poulsen M, Macfarlane D, Veness M, et al. Prospective analysis of the utility of 18-FDG PET in Merkel cell carcinoma of the skin: A Trans Tasman Radiation Oncology Group Study, TROG 09:03. J Med Imaging Radiat Oncol 2018. Available at: <https://www.ncbi.nlm.nih.gov/pubmed/29405630>.

189. Voog E, Biron P, Martin JP, Blay JY. Chemotherapy for patients with locally advanced or metastatic Merkel cell carcinoma. Cancer 1999;85:2589-2595. Available at: <http://www.ncbi.nlm.nih.gov/pubmed/10375107>.

190. Schneider S, Thurnher D, Erovic BM. Merkel cell carcinoma: interdisciplinary management of a rare disease. J Skin Cancer 2013;2013:189342. Available at: <http://www.ncbi.nlm.nih.gov/pubmed/23401779>.

191. Foote M, Veness M, Zarate D, Poulsen M. Merkel cell carcinoma: the prognostic implications of an occult primary in stage IIIB (nodal) disease. J Am Acad Dermatol 2012;67:395-399. Available at: <https://www.ncbi.nlm.nih.gov/pubmed/22030017>.

192. Tarantola TI, Vallow LA, Halyard MY, et al. Unknown primary Merkel cell carcinoma: 23 new cases and a review. J Am Acad Dermatol 2013;68:433-440. Available at: <https://www.ncbi.nlm.nih.gov/pubmed/23182060>.

193. Chen KT, Papavasiliou P, Edwards K, et al. A better prognosis for Merkel cell carcinoma of unknown primary origin. Am J Surg 2013;206:752-757. Available at: <https://www.ncbi.nlm.nih.gov/pubmed/23835211>.

194. Mehrany K, Otley CC, Weenig RH, et al. A meta-analysis of the prognostic significance of sentinel lymph node status in Merkel cell carcinoma. Dermatol Surg 2002;28:113-117; discussion 117. Available at: <http://www.ncbi.nlm.nih.gov/pubmed/11860419>.

195. Gunaratne DA, Howle JR, Veness MJ. Sentinel lymph node biopsy in Merkel cell carcinoma: a 15-year institutional experience and statistical analysis of 721 reported cases. Br J Dermatol 2016;174:273-281. Available at: <http://www.ncbi.nlm.nih.gov/pubmed/26480031>.

196. Jouary T, Kubica E, Dalle S, et al. Sentinel node status and immunosuppression: recurrence factors in localized Merkel cell carcinoma. Acta Derm Venereol 2015;95:835-840. Available at: <http://www.ncbi.nlm.nih.gov/pubmed/25784178>.

197. Sims JR, Grotz TE, Pockaj BA, et al. Sentinel lymph node biopsy in Merkel cell carcinoma: The Mayo Clinic experience of 150 patients. Surg Oncol 2018;27:11-17. Available at: <https://www.ncbi.nlm.nih.gov/pubmed/29549898>.



NCCN Guidelines Version 1.2022

Merkel Cell Carcinoma

198. Servy A, Maubec E, Sugier PE, et al. Merkel cell carcinoma: value of sentinel lymph-node status and adjuvant radiation therapy. *Ann Oncol* 2016;27:914-919. Available at: <http://www.ncbi.nlm.nih.gov/pubmed/26811346>.
199. Kachare SD, Wong JH, Vohra NA, et al. Sentinel lymph node biopsy is associated with improved survival in Merkel cell carcinoma. *Ann Surg Oncol* 2014;21:1624-1630. Available at: <https://www.ncbi.nlm.nih.gov/pubmed/24378985>.
200. Soult MC, Feliberti EC, Silverberg ML, Perry RR. Merkel cell carcinoma: high recurrence rate despite aggressive treatment. *J Surg Res* 2012;177:75-80. Available at: <https://www.ncbi.nlm.nih.gov/pubmed/22537840>.
201. Sattler E, Geimer T, Sick I, et al. Sentinel lymph node in Merkel cell carcinoma: To biopsy or not to biopsy? *J Dermatol* 2013;40:374-379. Available at: <http://www.ncbi.nlm.nih.gov/pubmed/23414107>.
202. Allen PJ, Busam K, Hill AD, et al. Immunohistochemical analysis of sentinel lymph nodes from patients with Merkel cell carcinoma. *Cancer* 2001;92:1650-1655. Available at: <http://www.ncbi.nlm.nih.gov/pubmed/11745244>.
203. Su LD, Lowe L, Bradford CR, et al. Immunostaining for cytokeratin 20 improves detection of micrometastatic Merkel cell carcinoma in sentinel lymph nodes. *J Am Acad Dermatol* 2002;46:661-666. Available at: <http://www.ncbi.nlm.nih.gov/pubmed/12004304>.
204. Schmalbach CE, Lowe L, Teknos TN, et al. Reliability of sentinel lymph node biopsy for regional staging of head and neck Merkel cell carcinoma. *Arch Otolaryngol Head Neck Surg* 2005;131:610-614. Available at: <http://www.ncbi.nlm.nih.gov/pubmed/16027284>.
205. Maza S, Trefzer U, Hofmann M, et al. Impact of sentinel lymph node biopsy in patients with Merkel cell carcinoma: results of a prospective study and review of the literature. *Eur J Nucl Med Mol Imaging* 2006;33:433-440. Available at: <https://www.ncbi.nlm.nih.gov/pubmed/16432719>.
206. Loyo M, Schussel J, Colantuoni E, et al. Detection of Merkel cell virus and correlation with histologic presence of Merkel cell carcinoma in sentinel lymph nodes. *Br J Cancer* 2012;106:1314-1319. Available at: <https://www.ncbi.nlm.nih.gov/pubmed/22415238>.
207. Righi A, Ascoli S, Caliendo V, et al. An ultrasonography-cytology protocol for the diagnostic management of regional nodes in a subset of patients with Merkel cell carcinoma of the skin. *Br J Dermatol* 2013;168:563-570. Available at: <https://www.ncbi.nlm.nih.gov/pubmed/23106631>.
208. Hoeller U, Mueller T, Schubert T, et al. Regional nodal relapse in surgically staged Merkel cell carcinoma. *Strahlenther Onkol* 2015;191:51-58. Available at: <https://www.ncbi.nlm.nih.gov/pubmed/25293726>.
209. Ko JS, Prieto VG, Elson PJ, et al. Histological pattern of Merkel cell carcinoma sentinel lymph node metastasis improves stratification of Stage III patients. *Mod Pathol* 2016;29:122-130. Available at: <http://www.ncbi.nlm.nih.gov/pubmed/26541273>.
210. Collins BT, Elmberger PG, Tani EM, et al. Fine-needle aspiration of Merkel cell carcinoma of the skin with cytomorphology and immunocytochemical correlation. *Diagn Cytopathol* 1998;18:251-257. Available at: <https://www.ncbi.nlm.nih.gov/pubmed/9557258>.
211. Shield PW, Crous H. Fine-needle aspiration cytology of Merkel cell carcinoma—a review of 69 cases. *Diagn Cytopathol* 2014;42:924-928. Available at: <https://www.ncbi.nlm.nih.gov/pubmed/24678011>.
212. Cipolletta Campanile A, Malzone MG, Sanna V, et al. Cytological and immunocytochemical features of Merkel cell carcinoma on fine needle cytology samples: A study of 22 cases. *Endocr Pathol* 2015;26:243-249. Available at: <https://www.ncbi.nlm.nih.gov/pubmed/25982258>.



NCCN Guidelines Version 1.2022

Merkel Cell Carcinoma

213. Wright GP, Holtzman MP. Surgical resection improves median overall survival with marginal improvement in long-term survival when compared with definitive radiotherapy in Merkel cell carcinoma: A propensity score matched analysis of the National Cancer Database. *Am J Surg* 2018;215:384-387. Available at: <https://www.ncbi.nlm.nih.gov/pubmed/29157891>.

214. Kukko H, Bohling T, Koljonen V, et al. Merkel cell carcinoma - a population-based epidemiological study in Finland with a clinical series of 181 cases. *Eur J Cancer* 2012;48:737-742. Available at: <https://www.ncbi.nlm.nih.gov/pubmed/21729823>.

215. Kim JA, Choi AH. Effect of radiation therapy on survival in patients with resected Merkel cell carcinoma: a propensity score surveillance, epidemiology, and end results database analysis. *JAMA Dermatol* 2013;149:831-838. Available at: <http://www.ncbi.nlm.nih.gov/pubmed/23864085>.

216. Jackson PC, Wallis K, Allgar V, et al. Merkel cell carcinoma in East Yorkshire: A case series and literature review of current management. *J Plast Reconstr Aesthet Surg* 2015;68:667-672. Available at: <https://www.ncbi.nlm.nih.gov/pubmed/25595515>.

217. Haymerle G, Fochtmann A, Kunstfeld R, et al. Merkel cell carcinoma: Overall survival after open biopsy versus wide local excision. *Head Neck* 2016;38 Suppl 1:E1014-1018. Available at: <https://www.ncbi.nlm.nih.gov/pubmed/26041367>.

218. Chen MM, Roman SA, Sosa JA, Judson BL. The role of adjuvant therapy in the management of head and neck merkel cell carcinoma: an analysis of 4815 patients. *JAMA Otolaryngol Head Neck Surg* 2015;141:137-141. Available at: <https://www.ncbi.nlm.nih.gov/pubmed/25474617>.

219. Vargo JA, Ghareeb ER, Balasubramani GK, Beriwal S. RE: Adjuvant radiation therapy and chemotherapy in Merkel cell carcinoma: Survival analyses of 6908 cases from the National Cancer Data Base. *J Natl Cancer Inst* 2017;109. Available at: <https://www.ncbi.nlm.nih.gov/pubmed/28423400>.

220. Singh B, Qureshi MM, Truong MT, Sahni D. Demographics and outcomes of stage I-II Merkel cell carcinoma treated with Mohs micrographic surgery compared with wide local excision in the National Cancer Data Base. *J Am Acad Dermatol* 2018. Available at: <https://www.ncbi.nlm.nih.gov/pubmed/29408552>.

221. Mattavelli I, Patuzzo R, Torri V, et al. Prognostic factors in Merkel cell carcinoma patients undergoing sentinel node biopsy. *Eur J Surg Oncol* 2017;43:1536-1541. Available at: <https://www.ncbi.nlm.nih.gov/pubmed/28583789>.

222. Yiengpruksawan A, Coit DG, Thaler HT, et al. Merkel cell carcinoma. Prognosis and management. *Arch Surg* 1991;126:1514-1519. Available at: <https://www.ncbi.nlm.nih.gov/pubmed/1842182>.

223. Allen PJ, Zhang ZF, Coit DG. Surgical management of Merkel cell carcinoma. *Ann Surg* 1999;229:97-105. Available at: <http://www.ncbi.nlm.nih.gov/pubmed/9923806>.

224. Lok B, Khan S, Mutter R, et al. Selective radiotherapy for the treatment of head and neck Merkel cell carcinoma. *Cancer* 2012;118:3937-3944. Available at: <http://www.ncbi.nlm.nih.gov/pubmed/22180314>.

225. Howle JR, Hughes TM, Gebiski V, Veness MJ. Merkel cell carcinoma: an Australian perspective and the importance of addressing the regional lymph nodes in clinically node-negative patients. *J Am Acad Dermatol* 2012;67:33-40. Available at: <https://www.ncbi.nlm.nih.gov/pubmed/21996296>.

226. Timmer FC, Klop WM, Relyveld GN, et al. Merkel cell carcinoma of the head and neck: emphasizing the risk of undertreatment. *Eur Arch Otorhinolaryngol* 2016;273:1243-1251. Available at: <https://www.ncbi.nlm.nih.gov/pubmed/25759258>.

227. Han AY, Patel PB, Anderson M, et al. Adjuvant radiation therapy improves patient survival in early-stage merkel cell carcinoma: A 15-year single-institution study. *Laryngoscope* 2018. Available at: <https://www.ncbi.nlm.nih.gov/pubmed/29314048>.



NCCN Guidelines Version 1.2022

Merkel Cell Carcinoma

228. Finnigan R, Hruby G, Wratten C, et al. The impact of preradiation residual disease volume on time to locoregional failure in cutaneous Merkel cell carcinoma--a TROG substudy. *Int J Radiat Oncol Biol Phys* 2013;86:91-95. Available at: <http://www.ncbi.nlm.nih.gov/pubmed/23290441>.

229. O'Connor WJ, Roenigk RK, Brodland DG. Merkel cell carcinoma. Comparison of Mohs micrographic surgery and wide excision in eighty-six patients. *Dermatol Surg* 1997;23:929-933. Available at: <http://www.ncbi.nlm.nih.gov/pubmed/9357504>.

230. Boyer JD, Zitelli JA, Brodland DG, D'Angelo G. Local control of primary Merkel cell carcinoma: review of 45 cases treated with Mohs micrographic surgery with and without adjuvant radiation. *J Am Acad Dermatol* 2002;47:885-892. Available at: <http://www.ncbi.nlm.nih.gov/pubmed/12451374>.

231. Senchenkov A, Barnes SA, Moran SL. Predictors of survival and recurrence in the surgical treatment of merkel cell carcinoma of the extremities. *J Surg Oncol* 2007;95:229-234. Available at: <http://www.ncbi.nlm.nih.gov/pubmed/17323336>.

232. Takagishi SR, Marx TE, Lewis C, et al. Postoperative radiation therapy is associated with a reduced risk of local recurrence among low risk Merkel cell carcinomas of the head and neck. *Adv Radiat Oncol* 2016;1:244-251. Available at: <https://www.ncbi.nlm.nih.gov/pubmed/28740894>.

233. Kline L, Coldiron B. Mohs micrographic surgery for the treatment of Merkel cell carcinoma. *Dermatol Surg* 2016;42:945-951. Available at: <https://www.ncbi.nlm.nih.gov/pubmed/27467228>.

234. Pennington BE, Leffell DJ. Mohs micrographic surgery: established uses and emerging trends. *Oncology (Williston Park)* 2005;19:1165-1171; discussion 1171-1162, 1175. Available at: <http://www.ncbi.nlm.nih.gov/pubmed/16255133>.

235. Dancy AL, Rayatt SS, Soon C, et al. Merkel cell carcinoma: a report of 34 cases and literature review. *J Plast Reconstr Aesthet Surg* 2006;59:1294-1299. Available at: <https://www.ncbi.nlm.nih.gov/pubmed/17113506>.

236. Fenig E, Brenner B, Katz A, et al. The role of radiation therapy and chemotherapy in the treatment of Merkel cell carcinoma. *Cancer* 1997;80:881-885. Available at: <https://www.ncbi.nlm.nih.gov/pubmed/9307187>.

237. Morrison WH, Peters LJ, Silva EG, et al. The essential role of radiation therapy in securing locoregional control of Merkel cell carcinoma. *Int J Radiat Oncol Biol Phys* 1990;19:583-591. Available at: <https://www.ncbi.nlm.nih.gov/pubmed/2211207>.

238. Mortier L, Mirabel X, Fournier C, et al. Radiotherapy alone for primary Merkel cell carcinoma. *Arch Dermatol* 2003;139:1587-1590. Available at: <https://www.ncbi.nlm.nih.gov/pubmed/14676075>.

239. Veness MJ, Perera L, McCourt J, et al. Merkel cell carcinoma: improved outcome with adjuvant radiotherapy. *ANZ J Surg* 2005;75:275-281. Available at: <https://www.ncbi.nlm.nih.gov/pubmed/15932436>.

240. Tsang G, O'Brien P, Robertson R, et al. All delays before radiotherapy risk progression of Merkel cell carcinoma. *Australas Radiol* 2004;48:371-375. Available at: <https://www.ncbi.nlm.nih.gov/pubmed/15344989>.

241. Clark JR, Veness MJ, Gilbert R, et al. Merkel cell carcinoma of the head and neck: is adjuvant radiotherapy necessary? *Head Neck* 2007;29:249-257. Available at: <https://www.ncbi.nlm.nih.gov/pubmed/17163472>.

242. Koh CS, Veness MJ. Role of definitive radiotherapy in treating patients with inoperable Merkel cell carcinoma: the Westmead Hospital experience and a review of the literature. *Australas J Dermatol* 2009;50:249-256. Available at: <https://www.ncbi.nlm.nih.gov/pubmed/19916967>.



243. Fang LC, Lemos B, Douglas J, et al. Radiation monotherapy as regional treatment for lymph node-positive Merkel cell carcinoma. *Cancer* 2010;116:1783-1790. Available at: <https://www.ncbi.nlm.nih.gov/pubmed/20162707>.

244. Samimi M, Touze A, Laude H, et al. Vitamin D deficiency is associated with greater tumor size and poorer outcome in Merkel cell carcinoma patients. *J Eur Acad Dermatol Venereol* 2014;28:298-308. Available at: <https://www.ncbi.nlm.nih.gov/pubmed/23368852>.

245. Fondain M, Du Thanh A, Bessaoud F, et al. Epidemiological trends in Merkel cell carcinoma in southern France: a registry-based study. *Br J Dermatol* 2017;176:1379-1381. Available at: <https://www.ncbi.nlm.nih.gov/pubmed/27515470>.

246. Gunaratne DA, Howle JR, Veness MJ. Definitive radiotherapy for Merkel cell carcinoma confers clinically meaningful in-field locoregional control: A review and analysis of the literature. *J Am Acad Dermatol* 2017;77:142-148 e141. Available at: <https://www.ncbi.nlm.nih.gov/pubmed/28495499>.

247. Mendenhall WM, Morris CG, Kirwan JM, et al. Management of cutaneous Merkel cell carcinoma. *Acta Oncol* 2018;57:320-323. Available at: <https://www.ncbi.nlm.nih.gov/pubmed/28712323>.

248. Shaw JH, Rumball E. Merkel cell tumour: clinical behaviour and treatment. *Br J Surg* 1991;78:138-142. Available at: <https://www.ncbi.nlm.nih.gov/pubmed/2015460>.

249. Veness M, Foote M, Gebiski V, Poulsen M. The role of radiotherapy alone in patients with merkel cell carcinoma: reporting the Australian experience of 43 patients. *Int J Radiat Oncol Biol Phys* 2010;78:703-709. Available at: <https://www.ncbi.nlm.nih.gov/pubmed/19939581>.

250. Sundaresan P, Hruby G, Hamilton A, et al. Definitive radiotherapy or chemoradiotherapy in the treatment of Merkel cell carcinoma. *Clin Oncol (R Coll Radiol)* 2012;24:e131-136. Available at: <https://www.ncbi.nlm.nih.gov/pubmed/22626522>.

251. Harrington C, Kwan W. Outcomes of Merkel cell carcinoma treated with radiotherapy without radical surgical excision. *Ann Surg Oncol* 2014;21:3401-3405. Available at: <https://www.ncbi.nlm.nih.gov/pubmed/25001091>.

252. Veness M, Howle J. Radiotherapy alone in patients with Merkel cell carcinoma: the Westmead Hospital experience of 41 patients. *Australas J Dermatol* 2015;56:19-24. Available at:

253. Bishop AJ, Garden AS, Gunn GB, et al. Merkel cell carcinoma of the head and neck: Favorable outcomes with radiotherapy. *Head Neck* 2016;38 Suppl 1:E452-458. Available at: <http://www.ncbi.nlm.nih.gov/pubmed/25645649>.

254. Grotz TE, Tarantola TI, Otley CC, et al. Natural history of merkel cell carcinoma following locoregional recurrence. *Ann Surg Oncol* 2012;19:2556-2562. Available at: <https://www.ncbi.nlm.nih.gov/pubmed/22453243>.

255. Tai PT, Yu E, Tonita J, Gilchrist J. Merkel cell carcinoma of the skin. *J Cutan Med Surg* 2000;4:186-195. Available at: <https://www.ncbi.nlm.nih.gov/pubmed/11231196>.

256. Mojica P, Smith D, Ellenhorn JD. Adjuvant radiation therapy is associated with improved survival in Merkel cell carcinoma of the skin. *J Clin Oncol* 2007;25:1043-1047. Available at: <http://www.ncbi.nlm.nih.gov/pubmed/17369567>.

257. Frohm ML, Griffith KA, Harms KL, et al. Recurrence and survival in patients with Merkel cell carcinoma undergoing surgery without adjuvant radiation therapy to the primary site. *JAMA Dermatol* 2016. Available at: <http://www.ncbi.nlm.nih.gov/pubmed/27248515>.

258. Strom T, Carr M, Zager JS, et al. Radiation therapy is associated with improved outcomes in Merkel cell carcinoma. *Ann Surg Oncol* 2016;23:3572-3578. Available at: <https://www.ncbi.nlm.nih.gov/pubmed/27251134>.



NCCN Guidelines Version 1.2022

Merkel Cell Carcinoma

259. Meeuwissen JA, Bourne RG, Kearsley JH. The importance of postoperative radiation therapy in the treatment of Merkel cell carcinoma. *Int J Radiat Oncol Biol Phys* 1995;31:325-331. Available at: <https://www.ncbi.nlm.nih.gov/pubmed/7836086>.

260. Poulsen MG, Rischin D, Porter I, et al. Does chemotherapy improve survival in high-risk stage I and II Merkel cell carcinoma of the skin? *Int J Radiat Oncol Biol Phys* 2006;64:114-119. Available at: <http://www.ncbi.nlm.nih.gov/pubmed/16125873>.

261. Strom T, Naghavi AO, Messina JL, et al. Improved local and regional control with radiotherapy for Merkel cell carcinoma of the head and neck. *Head Neck* 2017;39:48-55. Available at: <https://www.ncbi.nlm.nih.gov/pubmed/27300153>.

262. Tai P, Yu E, Assouline A, et al. Multimodality management for 145 cases of Merkel cell carcinoma. *Med Oncol* 2010;27:1260-1266. Available at: <https://www.ncbi.nlm.nih.gov/pubmed/19949898>.

263. Stokes JB, Graw KS, Dengel LT, et al. Patients with Merkel cell carcinoma tumors < or = 1.0 cm in diameter are unlikely to harbor regional lymph node metastasis. *J Clin Oncol* 2009;27:3772-3777. Available at: <https://www.ncbi.nlm.nih.gov/pubmed/19581538>.

264. Deneve JL, Messina JL, Marzban SS, et al. Merkel cell carcinoma of unknown primary origin. *Ann Surg Oncol* 2012;19:2360-2366. Available at: <https://www.ncbi.nlm.nih.gov/pubmed/22271206>.

265. Kouzmina M, Leikola J, Bohling T, Koljonen V. Positive sentinel lymph node biopsy predicts local metastases during the course of disease in Merkel cell carcinoma. *J Plast Surg Hand Surg* 2013;47:139-143. Available at: <https://www.ncbi.nlm.nih.gov/pubmed/23402426>.

266. Kokoska ER, Kokoska MS, Collins BT, et al. Early aggressive treatment for Merkel cell carcinoma improves outcome. *Am J Surg* 1997;174:688-693. Available at: <http://www.ncbi.nlm.nih.gov/pubmed/9409598>.

267. Grotz TE, Joseph RW, Pockaj BA, et al. Negative sentinel lymph node biopsy in Merkel cell carcinoma is associated with a low risk of same-nodal-basin recurrences. *Ann Surg Oncol* 2015;22:4060-4066. Available at: <http://www.ncbi.nlm.nih.gov/pubmed/25676844>.

268. Hasan S, Liu L, Triplet J, et al. The role of postoperative radiation and chemoradiation in merkel cell carcinoma: a systematic review of the literature. *Front Oncol* 2013;3:276. Available at: <https://www.ncbi.nlm.nih.gov/pubmed/24294591>.

269. Lewis KG, Weinstock MA, Weaver AL, Otley CC. Adjuvant local irradiation for Merkel cell carcinoma. *Arch Dermatol* 2006;142:693-700. Available at: <http://www.ncbi.nlm.nih.gov/pubmed/16785371>.

270. Ghadjar P, Kaanders JH, Poortmans P, et al. The essential role of radiotherapy in the treatment of Merkel cell carcinoma: a study from the Rare Cancer Network. *Int J Radiat Oncol Biol Phys* 2011;81:e583-591. Available at: <https://www.ncbi.nlm.nih.gov/pubmed/21775069>.

271. Jouary T, Leyral C, Dreno B, et al. Adjuvant prophylactic regional radiotherapy versus observation in stage I Merkel cell carcinoma: a multicentric prospective randomized study. *Ann Oncol* 2012;23:1074-1080. Available at: <http://www.ncbi.nlm.nih.gov/pubmed/21750118>.

272. Desch L, Kunstfeld R. Merkel cell carcinoma: chemotherapy and emerging new therapeutic options. *J Skin Cancer* 2013;2013:327150. Available at: <http://www.ncbi.nlm.nih.gov/pubmed/23476782>.

273. Saini AT, Miles BA. Merkel cell carcinoma of the head and neck: pathogenesis, current and emerging treatment options. *Onco Targets Ther* 2015;8:2157-2167. Available at: <https://www.ncbi.nlm.nih.gov/pubmed/26316785>.

274. Arron ST, Canavan T, Yu SS. Organ transplant recipients with Merkel cell carcinoma have reduced progression-free, overall, and disease-specific survival independent of stage at presentation. *J Am Acad Dermatol* 2014;71:684-690. Available at: <https://www.ncbi.nlm.nih.gov/pubmed/24993599>.



275. National Institutes of Health. Adjuvant Therapy of Completely Resected Merkel Cell Carcinoma With Immune Checkpoint Blocking Antibodies Versus Observation (ADMEC-O). Available at: <https://clinicaltrials.gov/ct2/show/record/NCT02196961>. Accessed May 3, 2018.

276. National Institutes of Health. Adjuvant Avelumab in Merkel Cell Cancer (ADAM). Available at: <https://clinicaltrials.gov/ct2/show/record/NCT03271372>. Accessed May 3, 2018.

277. Sharma D, Flora G, Grunberg SM. Chemotherapy of metastatic Merkel cell carcinoma: case report and review of the literature. *Am J Clin Oncol* 1991;14:166-169. Available at: <https://www.ncbi.nlm.nih.gov/pubmed/2028925>.

278. Tai PT, Yu E, Winquist E, et al. Chemotherapy in neuroendocrine/Merkel cell carcinoma of the skin: case series and review of 204 cases. *J Clin Oncol* 2000;18:2493-2499. Available at: <http://www.ncbi.nlm.nih.gov/pubmed/10856110>.

279. Iyer JG, Blom A, Doumani R, et al. Response rates and durability of chemotherapy among 62 patients with metastatic Merkel cell carcinoma. *Cancer Med* 2016;5:2294-2301. Available at: <https://www.ncbi.nlm.nih.gov/pubmed/27431483>.

280. Cowey CL, Mahnke L, Espirito J, et al. Real-world treatment outcomes in patients with metastatic Merkel cell carcinoma treated with chemotherapy in the USA. *Future Oncol* 2017;13:1699-1710. Available at: <https://www.ncbi.nlm.nih.gov/pubmed/28605939>.

281. Becker JC, Lorenz E, Ugurel S, et al. Evaluation of real-world treatment outcomes in patients with distant metastatic Merkel cell carcinoma following second-line chemotherapy in Europe. *Oncotarget* 2017;8:79731-79741. Available at: <https://www.ncbi.nlm.nih.gov/pubmed/29108353>.

282. Satpute SR, Ammakkanavar NR, Einhorn LH. Role of platinum-based chemotherapy for Merkel cell tumor in adjuvant and metastatic settings. *Journal of Clinical Oncology* 2014;32:9049-9049. Available at: http://ascopubs.org/doi/abs/10.1200/jco.2014.32.15_suppl.9049.

283. Mantripragada K, Birnbaum A. Response to anti-PD-1 therapy in metastatic Merkel cell carcinoma metastatic to the heart and pancreas. *Cureus* 2015;7:e403. Available at: <https://www.ncbi.nlm.nih.gov/pubmed/26824006>.

284. Patnaik A, Kang SP, Rasco D, et al. Phase I study of pembrolizumab (MK-3475; anti-PD-1 monoclonal antibody) in patients with advanced solid tumors. *Clin Cancer Res* 2015;21:4286-4293. Available at: <https://www.ncbi.nlm.nih.gov/pubmed/25977344>.

285. Walocko FM, Scheier BY, Harms PW, et al. Metastatic Merkel cell carcinoma response to nivolumab. *J Immunother Cancer* 2016;4:79. Available at: <https://www.ncbi.nlm.nih.gov/pubmed/27879975>.

286. Winkler JK, Bender C, Kratochwil C, et al. PD-1 blockade: a therapeutic option for treatment of metastatic Merkel cell carcinoma. *Br J Dermatol* 2017;176:216-219. Available at: <https://www.ncbi.nlm.nih.gov/pubmed/27038231>.

287. Winkler JK, Dimitrakopoulou-Strauss A, Sachpekidis C, et al. Ipilimumab has efficacy in metastatic Merkel cell carcinoma: a case series of five patients. *J Eur Acad Dermatol Venereol* 2017. Available at: <https://www.ncbi.nlm.nih.gov/pubmed/28256019>.

288. Heppt MV, Schlaak M, Eigentler TK, et al. Checkpoint blockade for metastatic melanoma and Merkel cell carcinoma in HIV-positive patients. *Ann Oncol* 2017;28:3104-3106. Available at: <https://www.ncbi.nlm.nih.gov/pubmed/28950303>.

289. Kaufman HL, Russell J, Hamid O, et al. Avelumab in patients with chemotherapy-refractory metastatic Merkel cell carcinoma: a multicentre, single-group, open-label, phase 2 trial. *Lancet Oncol* 2016;17:1374-1385. Available at: <https://www.ncbi.nlm.nih.gov/pubmed/27592805>.



NCCN Guidelines Version 1.2022

Merkel Cell Carcinoma

290. Kaufman HL, Russell JS, Hamid O, et al. Updated efficacy of avelumab in patients with previously treated metastatic Merkel cell carcinoma after ≥ 1 year of follow-up: JAVELIN Merkel 200, a phase 2 clinical trial. J Immunother Cancer 2018;6:7. Available at: <https://www.ncbi.nlm.nih.gov/pubmed/29347993>.

291. D'Angelo SP, Russell J, Lebbe C, et al. Efficacy and safety of first-line avelumab treatment in patients with stage IV metastatic Merkel cell carcinoma: A preplanned interim analysis of a clinical trial. JAMA Oncol 2018. Available at: <https://www.ncbi.nlm.nih.gov/pubmed/29566106>.

292. Nghiem PT, Bhatia S, Lipson EJ, et al. PD-1 blockade with pembrolizumab in advanced Merkel-cell carcinoma. N Engl J Med 2016;374:2542-2552. Available at: <https://www.ncbi.nlm.nih.gov/pubmed/27093365>.

293. Topalian SL, Bhatia S, Hollebecque A, et al. Non-comparative, open-label, multiple cohort, phase 1/2 study to evaluate nivolumab (NIVO) in patients with virus-associated tumors (CheckMate 358): Efficacy and safety in Merkel cell carcinoma (MCC) [abstract]. Presented at the American Association for Cancer Research Annual Meeting; Washington, DC. Abstract CT074.

294. Prescribing information: BAVENCIO (avelumab) injection, for intravenous use 2017. Available at: https://www.accessdata.fda.gov/drugsatfda_docs/label/2017/761049s002bl.pdf. Accessed May 3, 2018.

295. National Institutes of Health. A Study of T-VEC (Talimogene Laherparepvec) With or Without Radiotherapy for Melanoma, Merkel Cell Carcinoma, or Other Solid Tumors. Available at: <https://clinicaltrials.gov/ct2/show/record/NCT02819843>. Accessed May 3, 2018.

296. National Institutes of Health. Talimogene Laherparepvec and Nivolumab in Treating Patients With Refractory Lymphomas or Advanced or Refractory Non-melanoma Skin Cancers. Available at: <https://clinicaltrials.gov/ct2/show/record/NCT02978625>. Accessed May 3, 2018.

297. National Institutes of Health. Randomized Study of Nivolumab+Ipilimumab+/- SBRT for Metastatic Merkel Cell Carcinoma. Available at: <https://clinicaltrials.gov/ct2/show/record/NCT03071406>. Accessed May 3, 2018.

298. National Institutes of Health. Pembrolizumab With or Without Stereotactic Body Radiation Therapy in Treating Patients With Advanced or Metastatic Merkel Cell Cancer. Available at: <https://clinicaltrials.gov/ct2/show/record/NCT03304639>. Accessed May 3, 2018.

299. National Institutes of Health. T-VEC in Non-melanoma Skin Cancer (20139157 T-VEC). Available at: <https://clinicaltrials.gov/ct2/show/record/NCT03458117>. Accessed May 3, 2018.

300. Prescribing information: KEYTRUDA (pembrolizumab) for injection, for intravenous use. 2017. Available at: https://www.accessdata.fda.gov/drugsatfda_docs/label/2017/125514s031bl.pdf. Accessed May 3, 2018.

301. Prescribing information: OPDIVO (nivolumab) injection, for intravenous use. 2018. Available at: https://www.accessdata.fda.gov/drugsatfda_docs/label/2018/125554s058bl.pdf. Accessed May 3, 2018.

302. Haymerle G, Janik S, Fochtman A, et al. Expression of Merkelcell polyomavirus (MCPyV) large T-antigen in Merkel cell carcinoma lymph node metastases predicts poor outcome. PLoS One 2017;12:e0180426. Available at: <https://www.ncbi.nlm.nih.gov/pubmed/28763479>.