







Skin of Colour Skin Cancer Image Sources

Resource Title	Description	Examples
<p><u>Journal of the American Academy of Dermatology Skin of Color Image Atlas</u></p> 	<ul style="list-style-type: none"> • Can browse by disease • Linked to articles • Multiple examples of each disease available 	<p>Neoplasms- Malignant</p>  <p>Muir-Torre Syndrome A 4-mm hypopigmented papule (circled)</p> <p>View Article View Full-Size Image</p>  <p>Penile Basal Cell Carcinoma</p> <p>View Article View Full-Size Image</p>  <p>Periungual squamous cell carcinoma. Initial presentation as a scaly hyperpigmented papule at the base of the nail plate with longitudinal melanonychia and nail dystrophy</p>
<p><u>American Academy of Dermatology Section: SKIN CANCER IN PEOPLE OF COLOR</u></p> 	<ul style="list-style-type: none"> • Specific to skin cancer diagnosis and recognition 	   <p>Skin cancer in African Americans: Skin cancer often develops on parts of the body that get less sun like the bottom of the foot, lower leg, and palms. This cancer may also begin under a nail, around the anus, or on the genitals.</p>

Resource Title

Description

Examples

[Skin of Color Society_](#)
[Section: Skin of Color](#)
[Dermatology Textbooks](#)



- Offers more detailed information on SoC (skin of colour) disease presentations
- Geared towards audience of medical learners or healthcare professionals
- General public may find it difficult to access or understand this content

Offers a list of 34 textbooks that focus on skin of colour dermatologic disease presentations

Visual DX *

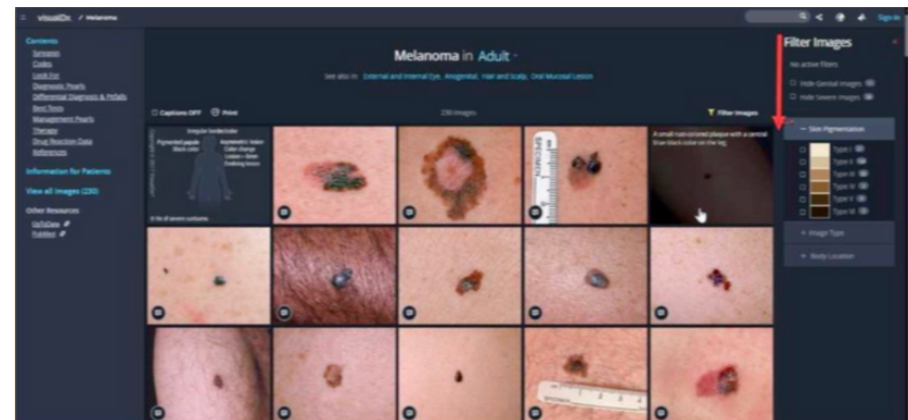
[image database](#)



[blog post](#)



- Clinical decision support tool with 45,000 images of medical conditions and a differential diagnosis builder with 3,500 diagnoses. VisualDx is a leading skin of colour atlas, and around a third of the images are skin type IV, V, or VI on the Fitzpatrick scale
- Requires subscription



Resource Title

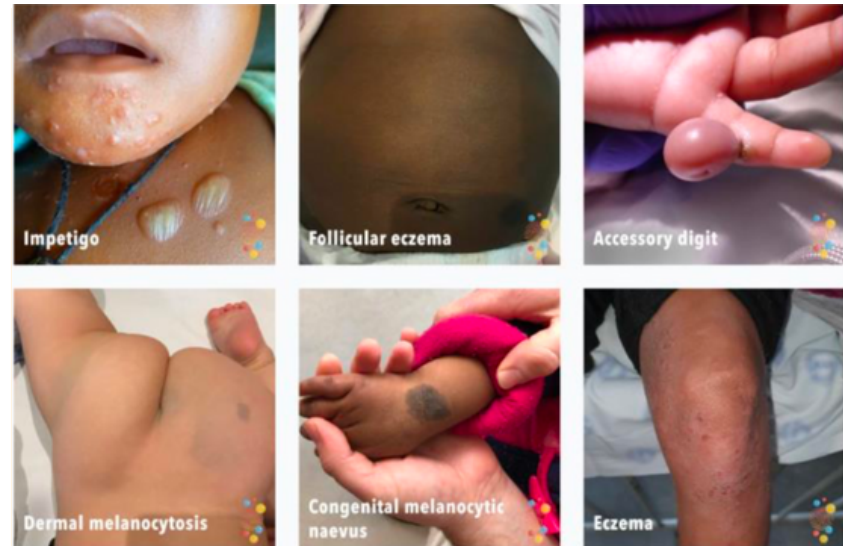Description

Examples

[Skin Deep](#)



- Database of images with SoC (skin of colour) dermatologic skin presentations
- Newly developed resource; skin cancer images to be added soon



[Derm Net New Zealand Skin of Color Database](#)



- Several examples of basal cell carcinoma, squamous cell carcinoma and melanoma available

DermNet NZ All about the skin Topics A-Z Images Skin Checker More

What is cutaneous squamous cell carcinoma?

Cutaneous [squamous cell carcinoma](#) (SCC) is a keratinocyte or non-melanoma [skin cancer](#) formed by the uncontrolled growth and replication of [squamous cells](#) in the epidermis. The [keratin](#) produced by these cells is a [horny protein](#) that normally forms skin, hair, and nails.

Cutaneous SCC is invasive into the dermis and may rarely metastasise (spread to other parts of the body). The more superficial forms of cutaneous SCC confined within the epidermis are known as [intraepidermal SCC](#) or SCC in situ.

Squamous cell carcinoma in skin of colour

Squamous cell carcinoma on the cheek Advanced squamous cell carcinoma arising Peri-anal squamous cell carcinoma in situ

Resource Title

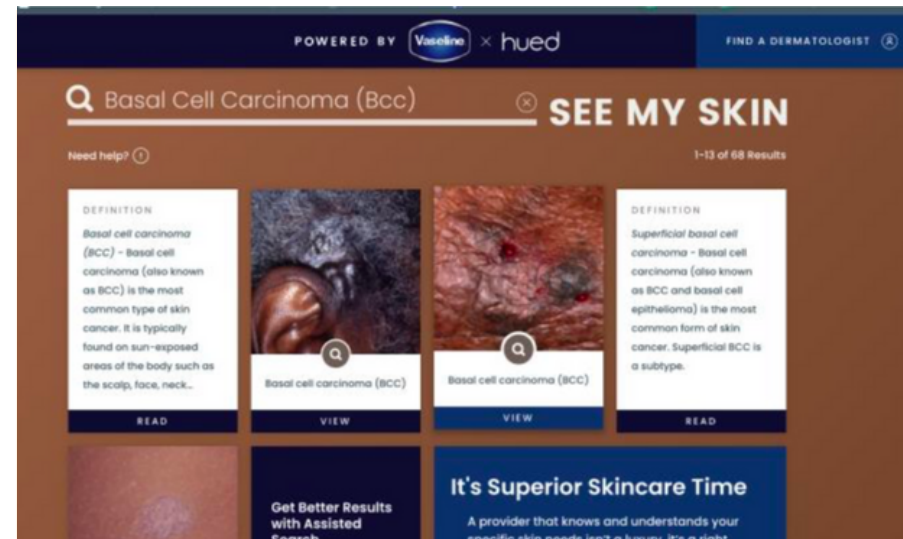
Description

Examples

See My Skin



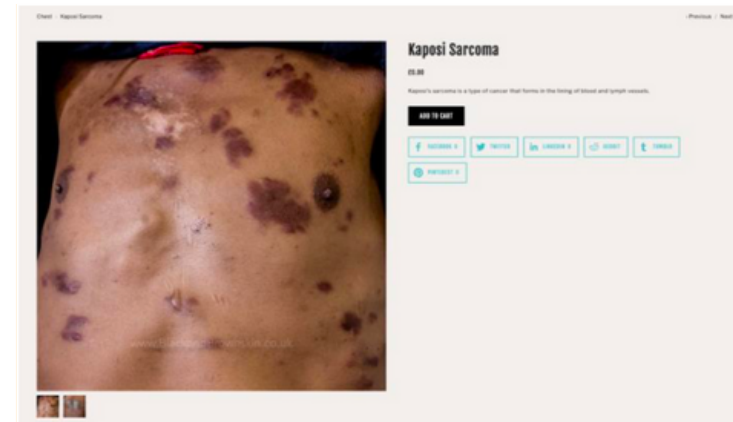
- Database designed to search for conditions on skin of colour and connect patients with dermatologists (focused on improving quality of care for Black, Latin and Indigenous populations through educational articles, access and data, and sourcing images in partnership with VisualDx)
- Several examples of basal cell carcinoma, squamous cell carcinoma and melanoma available



Mind the Gap



- Traditionally used as a handbook of clinical signs and symptoms in black and brown skin, but is now available to be downloaded online
- Limited examples of skin cancer varieties



Resource Title

[Brown Skin Matters](#)



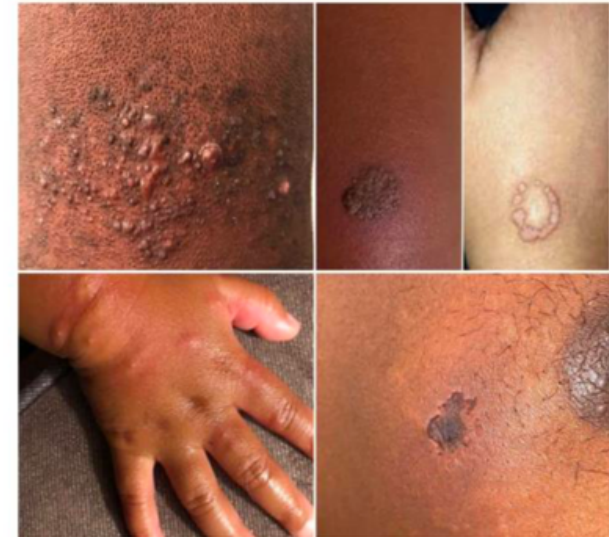Description

- Community sourced database of dermatological conditions on non-white skin
- Currently does not contain any skin cancer images
- Could help patients see examples of items on the skin cancer differential diagnosis

Examples

Browse skin conditions.

ACNE KELOIDALIS NUCHAE
ANNULAR WART
ANT BITES
BROWN RECLUSE BITE
CANDIDA DERMATITIS
CHICKENPOX
CHILBLAINS
COMEDONES
CONGENITAL DERMAL MELANOCYTOSIS
DERMATOGRAPHIA
DYSIDROTIC ECZEMA
ECZEMA
ERYTHEMA AB IGNE
ERYTHEMA MULTIFORME
FLEA BITES
GANOTTI-CROSTI
GIANT MELANOCYTIC NEVUS
HAND FOOT AND MOUTH
HEAT RASH
HIVES
HYPERPIGMENTATION



Prepared By: Rebecca Lena MD (C)
University of Toronto Faculty of Medicine
Version: 01/03/23

The following citation is recommended: Lena, Rebecca. Skin of Colour Skin Cancer Image Sources. Save Your Skin Foundation. January 2023, <https://saveyourskin.ca/wp-content/uploads/Skin-of-Color-Skin-Cancer-Image-Sources.pdf>. [Day Month Year of access].